

TIME OF DEATH,
DECOMPOSITION
AND
IDENTIFICATION

A N A T L A S

CAUSES OF DEATH ATLAS SERIES

TIME OF DEATH,
DECOMPOSITION
AND
IDENTIFICATION

AN ATLAS

JAY DIX
MICHAEL GRAHAM



CRC Press

Boca Raton London New York Washington, D.C.

FORENSIC PATHOLOGY ATLASES
CAUSES OF DEATH SERIES

Series Editor: Jay Dix

Asphyxia and Drowning: An Atlas

Jay Dix, Michael Graham and Randy Hanzlick

Investigation of Road Traffic Fatalities: An Atlas

Jay Dix, Michael Graham and Randy Hanzlick

Time of Death, Decomposition and Identification: An Atlas

Jay Dix and Michael Graham

Library of Congress Cataloging-in-Publication Data

Dix, Jay.

Time of death, decomposition and identification: an atlas / by Jay Dix
and Michael Graham.

p. cm.

Includes bibliographical references.

ISBN 0-8493-2367-3 (alk. paper)

1. Postmortem changes—Atlases. 2. Death—Time of—Atlases.

3. Dead—Identification—Atlases. I. Graham, Michael A. II. Title. III. Series.

[DNLM: 1. Forensic Medicine—methods—Atlases. 2. Postmortem changes—Atlases.

3. Time factors—Atlases W 617 D619t 1999]

RA1063.4.D59 1999

614'.1—dc21

99-050306

CIP

This book contains information obtained from authentic and highly regarded sources. Reprinted material is quoted with permission, and sources are indicated. A wide variety of references are listed. Reasonable efforts have been made to publish reliable data and information, but the author and the publisher cannot assume responsibility for the validity of all materials or for the consequences of their use.

Neither this book nor any part may be reproduced or transmitted in any form or by any means, electronic or mechanical, including photocopying, microfilming, and recording, or by any information storage or retrieval system, without prior permission in writing from the publisher.

The consent of CRC Press LLC does not extend to copying for general distribution, for promotion, for creating new works, or for resale. Specific permission must be obtained in writing from CRC Press LLC for such copying.

Direct all inquiries to CRC Press LLC, 2000 N.W. Corporate Blvd., Boca Raton, Florida 33431.

Trademark Notice: Product or corporate names may be trademarks or registered trademarks, and are used only for identification and explanation, without intent to infringe.

© 2000 by CRC Press LLC

No claim to original U.S. Government works

International Standard Book Number 0-8493-2367-3

Library of Congress Card Number 99-050306

Printed in the United States of America 2 3 4 5 6 7 8 9 0

Printed on acid-free paper

Preface

This is the first book in the Forensic Pathology: Causes of Death Atlas Series. It is intended for death investigators, law enforcement professionals, attorneys and anyone else who may be involved in forensic death cases. This particular book deals with the determination of the time of death, postmortem changes, and identification. These topics are important in virtually every death occurring in a forensic jurisdiction. The reader will learn through photographs and discussion how estimating the time of death can rarely be accomplished with scientific accuracy. The Atlas will show the numerous changes the body undergoes after death. Examples and discussion of how positive and probable identifications are made are also included.

J.D.

Table of Contents

Preface

1 **Time of Death (Postmortem Interval) and Decomposition**

Time of Death

Introduction

Rigor Mortis

Livor Mortis

Algor Mortis (Body Cooling)

Gastric Content

Chemical Analysis

Microscopic Analysis

Scene Investigation

Decomposition

Adipocere

Mummification

Anthropophagy

2 **Identification**

Positive Identification

Visual Identification

Fingerprints

Dental

Radiographs (X-rays)

DNA "Fingerprinting"

Presumptive Identification

Physical Features

Clothing and other Personal Property

Circumstances Surrounding Death

Skeletal Remains

3 Case Examples

Case 1 - Differential Decomposition

Discussion

Case 2 - Time of Death

Case 3 - Gastric Contents

Time of Death (Postmortem Interval) and Decomposition

1



Time of Death

Introduction

Establishing the time of death or the interval between the time of death and when a body is found (postmortem interval) typically cannot be determined with certainty. Unless death is witnessed, the exact time of death cannot be determined; however, sufficient information is often available to allow estimation of a range of time encompassing the actual moment of death. In general, the shorter the postmortem interval, the narrower the estimated time range. Conversely, a longer postmortem interval entails a broader range estimate and often a greater chance for error. No single observation about a dead body is a reliable or accurate indicator of the postmortem interval.

The most reliable estimates are based upon a combination of numerous observations made of the body and the scene of death. Observed conditions involving the body include rigor mortis, livor mortis, algor mortis and decomposition. The stomach contents may also help in determining the time of death. In addition to examining the body, it is also important to investigate the scene of death, during which time the environmental conditions should be documented. Environmental conditions, especially the temperature, are the most important factors affecting the changes the body undergoes after death. Observations made during the scene investigation help assess the body changes and may also offer additional information useful in estimating when death occurred. The combination of scene and body examinations will give the investigator the best chance of reliably estimating when death occurred.

The body observations should be made by someone with sufficient training and experience in death investigation as soon as possible after the body is found. The body should not be unnecessarily manipulated prior to making these observations. Changes in the environment, such as opening doors and windows or turning on air conditioning, should also be minimized until the observations are made.

Rigor Mortis

The muscles of the body initially become flaccid after death. Within 1–3 hours following death, the muscles begin to become noticeably increasingly rigid and the joints immobile (freeze) due to a process known as rigor mortis (postmortem rigidity, rigor). The chemical processes causing the muscles to stiffen are not clearly understood but are similar, although not identical, to physiologic muscle contraction in that both of these processes involve calcium and ATP/ADP. Rigor mortis involves the formation of locking chemical bridges between the muscle proteins actin and myosin and does not involve muscular shortening, while physiologic muscular contraction involves shortening of muscle as the actin molecules reversibly slide over the myosin molecules.

When a body stiffens, it remains in that position until rigor passes or it is physically overcome (broken), such as when a joint is forcibly moved. Since the chemical process of rigor is irreversible, fully developed rigor will not recur in an area in which it has been broken or in an area in which it has already passed. However, if rigor is overcome prior to its full development the process will continue to completion, resulting in the apparent recurrence of rigor in that area, albeit to less than expected “full” stiffness.

All muscles of the body begin to stiffen at the same time after death. However, the stiffening becomes noticeable in the smaller muscle groups before the larger groups, giving the appearance that rigor mortis proceeds at different rates in the various muscle groups. Stiffness is usually apparent first in the jaw, then the elbows and finally the knees. A body is said to be in complete or full rigor when the jaw, elbow and knee joints are immovable. The ability to passively move a joint is dependent on the amount of muscle controlling the joint. Rigor involving a joint with a small amount of muscle such as the finger is easily overcome, while it may be difficult to move a joint such as the elbow, which is connected to relatively large muscles. As a rule, men will have stronger rigor than women since men typically have a larger muscle mass than women. Large muscles, especially in muscular individuals, may become so resistant to stretching that it may require the efforts of more than one person to move a large joint. Occasionally, the bone may break before the rigor mortis is overcome. Conversely, rigor may be poorly formed or not apparent in individuals with little muscle mass, such as infants or emaciated adults.

Complete rigor takes approximately 10–12 hours to fully develop in an average size adult when the environmental temperature is 70–75°F. The body will remain stiff for 24–36 hours at this same temperature before decomposition causes the muscles to begin to appreciably loosen, apparently in the same order they stiffened.

The problem with relying on this time sequence for rigor mortis in estimating the postmortem interval is that a number of factors influence the course of rigor mortis. Rigor mortis is affected by the environmental temperature, the internal body temperature and the decedent's activity prior to death.

Rigor mortis is most affected by the environmental temperature. Elevated temperatures will accelerate the appearance and disappearance of rigor. Rigor involving a body lying in a field will come and pass quicker on a hot summer day than on a cold winter one. The rate of development and disappearance of rigor will be affected by temperature changes experienced by the body, such as occur during the heat of day and the coolness of night.

Rigor is also affected by the decedent's internal body temperature and activity prior to death. Higher body temperatures at the time of death and conditions causing more lactic acid production cause rigor to develop more quickly. For example, a person who dies having a fever from an infection such as pneumonia may develop rigor sooner than a person with a normal body temperature. Accelerated rigor may also be seen in persons dying with hyperthermia even though the environmental temperature may be normal, such as may occur in deaths related to cocaine, PCP or methamphetamine.

The onset of rigor may also occur more quickly if strenuous physical activity takes place immediately prior to death. For example, a person who runs away from an assailant before being shot or stabbed may develop rigor sooner than if there were no intense physical activity. The accelerated rigor is due to a combination of increased body temperature and increased production of lactic acid.

Rarely, rigor mortis may become apparent within minutes of death. This “cadaveric spasm” is usually associated with extreme physical activity just prior to death. It has also been associated with some other circumstances such as electrocution.

In contrast to elevated environmental temperature, cold conditions may retard or prevent rigor mortis. The process will begin or accelerate when the body is allowed to warm. If a body is not in complete rigor and is placed in refrigeration the process will slow down and may stop. Rigor may proceed to completion when the body is warmed. The stiffness of rigor must be differentiated from muscle hardening or freezing due to very cold weather. Under such environmental conditions, rigor may be difficult to evaluate.

Rigor mortis will also aid the investigator in determining if the body has been moved. If an investigator arrives on the scene and finds an unsupported arm or leg sticking up in the air, the investigator knows the decedent has been moved after rigor has set in. A person may die with the arms or legs in the air, but gravity will prevent the unsupported extremities from remaining there after death.

Livor Mortis

Livor mortis (postmortem hypostasis, lividity) is the discoloration of the body after death due to the gravitational settling of blood which is no longer being pumped through the body by the heart.

Livor mortis is usually noticeable approximately 1 hour after death and is often apparent earlier, within 20–30 minutes. The discoloration increases in intensity and usually becomes “fixed” in about 8–10 hours; however, the time interval to fixation is unpredictable and may be significantly longer or, occasionally, shorter than the “typical” 8–10 hours. Prior to fixation, the body can be moved many times and the blood will resettle each time into the dependent areas. However, after fixation, the blood will remain where it has already settled even if the body is repositioned. Fixation is a progressive process that is not all or nothing. Thus, if a body with some fixed livor is moved, there may be some blood that is not fixed and which is able to resettle. In such a case, discoloration will be seen in the repositioned dependent areas as well as in the original dependent areas. The intensity of the livor in each area will depend on the extent of fixation when the body was moved. Patterns of livor mortis in non-dependent areas indicate the body or body part has been moved after death. Individuals dying of some natural diseases, often involving terminal congestive heart failure, may have intense congestion of the head, neck, shoulders and upper chest, resulting in discoloration of these areas that appears to be similar to livor mortis except that it is not confined to dependent areas. Similar discoloration may also be seen in some cases of mechanical asphyxia. Discoloration due to blood congesting vessels that is not related to gravitational settling needs to be differentiated from livor mortis. Rarely, “lividity” has been observed in living people who have severe cardiovascular disturbances such as congestive heart failure.

The formation of livor may be hindered or prevented by pressure applied to the body’s surface because the small blood vessels become compressed and blood is prevented from settling into them. For example, if a body is lying on its back, pale areas will typically be found over the scapulae, buttocks and calves. In addition, any object pressing against the skin with sufficient pressure to compress small blood vessels will prevent blood from draining into them. Pale marks within zones of livor mortis may be caused by tight clothing (bra, underpants, belts), surface irregularities (wrinkled clothing or

bedding) or objects abutting the surface (coins in a pocket, marble on the floor). These patterns enable the investigator to judge if the body has been moved and to help in reconstructing the body's previous position.

Lividity tends to be violaceous or purple in a light-skinned individual and darker in someone with darker skin. Livor may not be apparent in a darkly pigmented person. People who die from extensive blood loss or who were severely anemic may have light or no apparent livor due to the small amount of blood or hemoglobin in their vascular system.

In certain causes of death, livor mortis may take on a different color. Carbon monoxide poisoning, cyanide poisoning and hypothermia are often associated with livor mortis that appears bright red or pink. Similar coloration of the livor may be induced during refrigeration of the body. It is common to see red edges outlining the typical purple livor mortis at the time of autopsy in a body that has been in the morgue's refrigerator overnight. Occasionally, most often in infants, the livor may be entirely red after the body has been in the morgue cooler overnight. Brown lividity has been described in deaths caused by potassium chlorate and in deaths caused by nitrobenzene poisoning.

Livor mortis will be visible until the body becomes discolored during decomposition. Color changes due to decomposition vary and include combinations of red, green, brown and black. The decomposition-induced changes will obscure the livor pattern and interfere with its interpretation. The examiner may not be able to determine whether the livor mortis is on the back or the front of the body if decomposition is sufficiently advanced.

In some cases, it may be difficult to distinguish livor mortis from contusion. In other cases, livor mortis may obscure the presence of contusion. An incision into an area of lividity will demonstrate blood confined to blood vessels, whereas an area of contusion will have extravasated blood within the soft tissues. Decomposition may add further difficulty in recognizing contusions and distinguishing them from livor mortis.

Occasionally, small blood vessels engorged with settled blood may passively rupture, allowing the blood to seep out of the vessel and create small areas of "hemorrhage." These extravasations, called Tardieu spots, are particularly common in distal extremities of hanging victims and generally measure less than 3/16" in diameter. They can also be present in any part of the body which is in a dependent position for many hours, especially just prior to the onset of decomposition as the blood vessels lose their structural integrity and leak. They should not be mistaken for the smaller pinpoint hemorrhages called petechiae. Petechiae may occur when death is accompanied by a sudden increase in venous pressure such as the terminal onset of profound heart failure or in asphyxial deaths involving compression of the chest or jugular veins as may occur in compression asphyxia or manual

strangulation. Petechiae are often seen on the face, especially on and around the eyes. If a person lies face down and is in this position for many hours or days, blood may accumulate in the small blood vessels of the eyes and orbit, resulting in a hemorrhagic or bloody appearance (“raccoon” eyes) that may falsely suggest the presence of trauma. The red/brown drying artifact of the conjunctivae (tache noire de sclerotic) which occurs when the eyes are partially open after death also should not be confused with livor mortis.

Algor Mortis (Body Cooling)

After death, the body equilibrates with the surrounding environmental temperature. Although this usually involves algor mortis (cooling of the body), in some cases, such as a body laying on a sidewalk in direct sunlight, the body may absorb heat. However, in most cases, the body will progressively lose temperature until it equilibrates with its environment. Many studies have examined this progressive decrease in body temperature to attempt to develop formulae which could be used to calculate the postmortem interval. Unfortunately, a number of variables affect postmortem cooling which precludes its use as an accurate method of predicting the postmortem interval. However, measuring body temperature may be useful in estimating the postmortem interval when considered in conjunction with other postmortem observations and when its limitations are recognized. In general, evaluating a decrease in body temperature is most helpful within the first 10–12 hours after death when the body is in a cool environment (70–75°F). During this time, assuming a normal antemortem temperature and a 70–75°F environment, the average size body cools at approximately 1 1/2°F per hour. However, the rate of cooling is affected by several variables and is not necessarily uniform. The rates of cooling at the ends of the curve are slower than the rates in the midportion. The body may not appreciably lose temperature in the initial hours after death and may, in fact, have an initial slight rise in temperature. Bodies with more insulation (fat, clothing) cool more slowly and those with less insulation cool more rapidly. Other problems in calculating the postmortem temperature using the rate of cooling include errors in assuming the initial internal temperature was 98.6°F and the environmental temperature was a constant 70–75°F. Errors in calculation would result if the antemortem body temperature was elevated due to infection, drug toxicity or physical exertion. Furthermore, the outside temperature is rarely a constant 70–75°F. Significant deviations from this environmental temperature may affect the shape and slope of the cooling curve. Elevated environmental temperatures may retard cooling (and, as noted above, may actually cause the body to absorb heat) and a cold environment may hasten it.

As the body gets cold, the fat in the soft tissues under the skin solidifies and will assume the shape of anything it rests against, causing unusual shapes

and distortions of the skin. Outlines of other body parts (such as hands) and items such as tree bark or sticks are common. The folds of skin around the neck may simulate a ligature mark.

If the body is in a very cold environment, it may freeze. Freezing severely limits an estimation of the postmortem interval except to say that the body has been dead long enough to freeze. Once the body begins to thaw, decomposition progresses rapidly. The rapidity of the changes may be impressive and may sometimes be seen in the short time between the onset and the end of the autopsy.

If the body temperature is going to be used to help estimate the postmortem interval, the body temperature should be taken as soon as possible after the body is discovered and the environmental temperature should be maintained and also measured. The temperature should ideally be taken at least twice, with a period of approximately 1 hour between the measurements to better define the actual rate of cooling (at least in that time). Liver and, less commonly, rectal temperatures are the most commonly used measurements of body core temperature. Oral or axillary temperature measurements are not valid. For the reasons previously noted, an estimate of the postmortem interval based solely on cooling of the body is, at best, a crude estimate.

It must be remembered that the environmental temperature measured at the time the body temperature is measured may not be indicative of the environmental conditions the body has been exposed to during a significant portion of the postmortem interval. A body lying outside may be subjected to wide variations in the environmental temperature. A body in a building may also be subject to some variations in temperature, such as may be due to changing sun exposure or a programmable thermostat. Changes in environmental conditions may also be brought about by investigators at the death scene who may open doors and windows, turn on air conditioning, etc.

Gastric Contents

The total volume and a description of food, liquid or other material present in the stomach should be recorded at autopsy. This information is helpful not only for identifying the composition of the decedent's last meal, but also for estimating the time of the last meal. For example, if a body is discovered in the evening and only breakfast-type food is present in the stomach, this finding would suggest that death occurred in the morning. In addition, gastric emptying time can be useful if taken in context with other information. In general, a light meal may take only a couple of hours to pass through the stomach into the small intestine while a heavy meal might take up to 6 hours. Some foods such as celery, onion, potato, corn and tomato skins typically take longer than meat or other foods to exit the stomach. Thus, if the time of the last meal is known, the state of gastric emptying may suggest

when death occurred in relation to the ingestion of the last meal. However, the rate of digestion and gastric emptying is affected by the mental and physical state of the victim prior to death. A person under mental or physical duress may have either a slower or quicker than normal gastric emptying time. It is not uncommon to examine the stomach contents of persons who have died after being in the hospital in a coma for several days due to a head injury, only to find that the stomach is full of nearly undigested food which was ingested prior to sustaining the head injury. Identification of the gastric contents also may allow investigators to identify when and where the victim last ate. For example, undigested pasta with a certain distinct sauce may be traced to a particular restaurant where the decedent was seen to eat at a particular time (and with a particular person).

Chemical Analyses

Various components of blood, cerebrospinal fluid and vitreous humor have been studied as a means to determine time of death. Unfortunately, none of these studies have yielded conclusive means to identify when someone died. The concentration and rate of rise of potassium in the vitreous fluid have received the most attention over the years. Its use is limited because of wide individual variation.

Microscopic Analyses

The body undergoes changes at the cellular level long before any changes can be seen with the unaided eye. Cells begin to die and enzymes may begin to digest the tissues at and around their sites of origin. Death and disintegration of cells and tissues becomes apparent microscopically. This process, called autolysis, only occurs after death. This process is different than the process of necrosis which is the death of cells and tissues that occurs when the individual is still alive. Autolysis occurs at different rates in different tissues. Tissues rich in digestive enzymes are most readily subject to autolytic changes.

Autolysis is readily seen with the microscope and may be apparent grossly. The cellular architecture appears to fade away or, in the case of tissues rich in digestive enzymes, dissolve. However, the ghosts of many of the cellular elements and their borders remain discernible into the decomposition process. There is no reaction by the body's immune or inflammatory system. If there is little or no autolysis then the postmortem interval was short or the person died under circumstances that would inhibit autolysis, such as death in a cold environment.

If cells are injured or die while a person is alive, there will be an inflammatory response to the injury if the person survives long enough. The type of response is somewhat dependent on the type of injury and the type of

tissue that is injured. The presence or absence of an inflammatory reaction may suggest the interval between the injury and death. Inflammatory responses occur at different rates in various tissues and are influenced by a number of factors including age, state of health and medications. An injury lacking an inflammatory response suggests it occurred in close proximity to the time of death.

The nature and extent of an inflammatory response may help determine the interval between the onset of the injury and the time of death. An illustrative example is a child who dies from an abdominal infection (peritonitis) caused by a ruptured intestine due to a blow to the abdomen. The inflammation around the bowel injury contains acute inflammation, but also chronic inflammatory cells and cells that produce scar tissue (fibroblasts) as well as a large amount of breakdown products of blood (hemosiderin). This appearance would indicate the injury had been received several days prior to death.

Scene Investigation

Besides the above changes involving the body, other information from the scene may help in determining the time of death. Some of this information involves the body and other details do not.

Insects attracted to the body (or to other insects already on the body) can be collected and saved for evaluation by an entomologist. An entomologist will be able to identify the various types of insects as well as their stages of development. Since each developmental stage lasts for a reasonably predictable time, the entomologist can calculate how long the various insects have been on the body. If live larvae and pupae are available, the entomologist can let them develop in the laboratory to more accurately define the length of their developmental stages under prescribed conditions. Potential effects of differences between laboratory conditions and the conditions the body was exposed to in the environment on the development of the insects must be taken into account when estimating the postmortem interval. The time frame developed by the entomologist represents the minimum time the body has been dead because a body may have been dead for some period of time prior to insect infestation. The entomologist is also able to determine what insects are active at particular times of the year and how long it typically takes for particular insects to invade the body. The entomologist also may be helpful in establishing if a body has been moved and, potentially, where it originated by identifying insects on the body that are not part of the local population and by identifying insects restricted to specific locales.

Experts in plant biology may be helpful in determining the postmortem interval. They may also be helpful in determining if the body has been moved and where it originated. The postmortem interval estimation provided by the botanist is usually in terms of months, years or seasons. They analyze

plant specimens recovered from the clothing, crime scene or body location. Plant material, including leaves, twigs and roots can be analyzed as to origin, time of year of presence and development. Pollen, fungi and algae may also be found and analyzed. The identification of the nature of plant material within digested gastric material may offer clues to the contents of the decedent's last meal.

Information from a scene not associated with the body may also be useful in estimating the time of death. For example, clues from a house or apartment may shed light on when death occurred — when were the mail and newspaper last picked up? Were the lights or television on? What food, if any, was being prepared? Was a major appliance on? Was there any indication as to activities an individual was performing, had completed or was contemplating? How was the person dressed? When was the computer last accessed?

Decomposition

The environment is a major determinant of the type of decomposition the body undergoes and the rate at which it proceeds. Bodies that are buried in earth, submerged in water, left in the hot sun or placed in a cool basement will not look the same after the same postmortem interval.

In general, as rigor passes, green discoloration of the skin becomes evident. The green discoloration typically begins on the abdomen and then spreads to the rest of the body. At room temperature, the right lower abdomen turns green at about 24 hours after death and the entire abdomen is green by 36 hours. As with other postmortem changes, the onset and progression of the green discoloration is quite variable. The spread of the green discoloration is not uniform. Some areas do not turn green because of the body's position, clothing or other factors. Some bodies will have red and/or black discoloration and may lack green discoloration. As discoloration progresses, the body will begin to swell due to the production of gas by bacteria. These bacteria are normal inhabitants of the large intestine (colon). After the person dies, the bacteria gain access to the vascular system through which they spread throughout the body where they proliferate. This bacterial overgrowth is promoted in warm weather and retarded in cold conditions. The bacteria that make the gases (methane and others) do not represent a hazard to the death investigator or pathologist.

Generally, as the body begins to bloat, the blood begins to break down (hemolyze) within the blood vessels and the outer layers of the skin (epidermis) begin to slip off the body. The hair will also loosen and slip off with the skin. Skin which slips off the hands and fingers will contain the decedent's fingerprints. This skin should be retained for printing if the decedent's identity is in question. Since the fingerprint pattern is actually based in the dermis

which remains on the body, the fingers from which the outer layers of the skin are absent can be printed. Obtaining adequate prints from decomposing tissue is often technically difficult but a variety of specialized techniques have been developed to optimize this procedure. As bloating continues, fluid may build up under the slipping skin, causing blisters to form. These fluid-filled blisters should not be confused with antemortem burns.

During the stages of bloating and skin slippage, blood within the blood vessels begins to degenerate and will stain the walls of the blood vessels. The degenerated blood will react with hydrogen sulfide made by bacteria and result in black staining of the blood vessels. The blood vessels that are close to the surface become visible as a reticulated pattern called “marbling.”

Also during the bloating stage, bloody fluid may exude from the body’s orifices, especially the nose and mouth. Gas pressure forces decomposed blood out of the lungs and airways, a phenomenon called “purging.” Fluid emanating from the nose and mouth should not be mistaken as a sign of trauma. On occasion, a marked amount of fluid will be purged and extensively stain the material, such as bedding or carpet, on which the decedent is lying. Increased pressure within body cavities and soft tissues may also cause the skin to tear. This most commonly occurs in areas of previous surgical incisions.

The body’s tissues and organs soften during decomposition, eventually to degenerate into a mass of unrecognizable tissue. Continued decomposition may lead to liquefaction of the tissues. At this stage, the brain will pour from the cranial cavity as an amorphous mass when the skull cap is removed during autopsy. Large accumulations of blood and skull fractures may be evident, but other subtler abnormalities will not be discerned. Examination of the other internal organs for diseases or injuries will also be problematic at this stage. The internal organs may be ingested by insects and other animals that have invaded the body.

Following the phases of “wet decomposition” the surface tissues will dry, collapse and darken to assume a leathery texture. Residual organs and tissues will also dessicate and shrink. Depending on the environment and the length of time since death, the body may eventually progress to skeletonization. The time for this to occur is extremely variable. For example, a body exposed to a 100°F environmental temperature with high humidity may completely decompose to a skeleton within a few weeks. In contrast, a body exposed to a 65°F environment may not skeletonize for months or years. Also, if a person dies in arid conditions, the body may mummify and complete skeletonization may not occur. Insect and animal activity may facilitate skeletonization.

Decomposition is associated with a myriad of odors, most of them unpleasant. The smell emanating from a decomposing body is not easy to describe. However, anyone who has smelled a dead animal along the side of the road readily recognizes the source of the smell. The body is most odiferous

during the wet stages of decomposition when gas and putrefactive amine production is highest. Bodies undergoing decomposition in water during the summer months may be particularly odiferous, especially after being out of the water for several hours. In general, the smell tends to dissipate as less and less soft tissue remains on the body. Mummified and partially skeletonized remains tend to have a more musty odor. Completely skeletonized remains may be essentially odor free.

As noted above, the environment in which a body lies is critical to the rate at which it will decompose. In general, a body decomposing above ground for a week may look similar to a body that has been under water for 2 weeks or one that has been buried in the ground for 6–8 weeks. This is a generalization and should only serve as a reminder that an uncovered body decomposes more rapidly than one that is covered or shielded.

The rate of decomposition in buried bodies is extremely variable. The climate and soil conditions play a part in how quickly decomposition will occur. The type of decomposition may also be different under various conditions. It is not uncommon for two bodies buried under different circumstances for the same length of time to appear markedly different. This also holds true for bodies that have undergone embalming prior to burial. Well-embalmed bodies in airtight caskets and vaults may remain in relatively good condition for years. However, bodies buried in caskets that fill with water may decompose within weeks.

Decomposition is not necessarily a uniform process and may be quite asymmetric. For example, decomposition will occur more rapidly in areas of injuries. If a person is struck on the head and the scalp is torn in that area, decomposition may be much more advanced on the head than the remainder of the body. Flies preferentially lay eggs in moist areas of the body such as eyes, nose, mouth, injured sites, anogenital orifices and body creases (e.g., axillae). Larvae are attracted to injured areas where they feed on exposed blood proteins and cause accelerated decomposition. Asymmetric decomposition may result in skeletonization restricted to one part of the body. For example, a decedent who was kneeling with his face on the ground had decomposition to the bone involving the side of the face touching the ground while the other side of the face was only discolored. The body had been in the woods for 2 weeks during cool temperatures.

After a body is discovered, it is usually refrigerated until a postmortem examination is performed or until final disposition. Decomposition will usually slow down or cease if a body is refrigerated. When re-exposed to room temperature the rate of decomposition will be accelerated because bacteria which have already disseminated will proliferate. Recognition of this accelerated decomposition is particularly important when a person dies in a cold environment and is moved to a warmer one. Accelerated decomposition is also commonly seen in corpses that have been submerged in bodies of water for prolonged periods.

A word of caution — the body at the scene may appear quite different than it does at the time of the autopsy. This may not present a significant problem if the same jurisdiction performs the investigation and the post-mortem examination. However, if the investigating agency and the pathologist are not in the same jurisdiction, problems in interpretation may arise. A body with minimal decomposition evident at the scene may be markedly more decomposed when viewed by the pathologist the next day or later after discovery. It is a good idea in such cases to have photographs of the body at the scene available for evaluation by the pathologist.

Under certain environmental conditions, decomposition may feature the formation of adipocere or mummification.

Adipocere

Adipocere is a term derived from Latin which literally means “fat” (adipo) “wax” (cera). It refers to a hard gray-white waxy substance formed during decomposition. It is an uncommon change, occurring particularly in bodies buried for an extended period of time in cool, moist environments and is most commonly seen after bodies have been submerged in water during the winter months. Not all bodies having adipocere are found in water. For example, bodies found in plastic bags which provide a moist environment may also undergo this change.

The formation of this substance requires fat. The fatty tissue beneath the skin begins to saponify (turn into soap). Generally, women and children form adipocere more readily because they have a higher fat content. The hardening usually takes a few months to fully develop but rarely can be fully developed within 4 weeks. It develops more completely in submerged bodies. Once fully developed, this process will keep the remainder of the body relatively well-preserved for months or years. The exterior of the body remains white and the outermost layers of the skin slip off. There may be “goose bumps” due to fixation of the arrector pili muscles of the hair shafts. Unlike the usual decompositional process, there may be no green discoloration or significant bloating since the cold temperatures inhibit the bacteria which normally proliferate and form gas.

Adipocere initially forms on the dependent parts of the body. For bodies totally submerged in water, adipocere will usually be distributed quite evenly over all body surfaces. Occasionally, there may be differential formation between those parts of the body that are clothed and those parts unclothed. Differential formation may also occur in areas of injury.

Mummification

Mummification occurs in hot dry environments where the body is able to dehydrate and bacterial proliferation is minimal. The skin becomes dark, dry and leathery. The internal organs desiccate and shrink. Most mummification

occurs in the summer months but may also occur during the winter if the temperature is warm enough. An entire body can mummify in a few days to weeks. As the skin dries and hardens, the soft tissues decompose. After a few weeks, an entire body may appear preserved with some shrinkage due to dehydration. If, however, an incision is made through the skin, soft tissues, fat and internal organs may be virtually absent with the body resembling a “bag of bones.” Once the body is in this state, it may remain preserved for many years unless the skin is torn or broken. Mummification localized to certain parts of the body is relatively common. Mummification of the fingers and toes occurs readily in relatively dry environments regardless of temperature.

Anthropophagia

Insects and other animals will feed on the body after death, if it is accessible. This is common both indoors and outdoors. Roaches and ants may cause yellow/brown erosions of the skin that may resemble abrasions and confuse examiners. Ant and roach bites on the skin of children dying of SIDS have been misconstrued as evidence of abuse. Insects and their larvae play a major role in the defleshing of a body during decomposition.

Larger animals, including household pets, will also feed on a dead body. Pet cats and dogs will chew on their dead owners if left alone and hungry. Rodents, raccoons, possums and other feral animals may also cause considerable damage to the body. Most of these postmortem injuries are readily recognized by either the pathologist or the consulting anthropologist. Rarely does an animal consume an entire body. However, animals may spread parts of the remains over a wide area.



Figure 1.1 This man was found in this position the day after he died. His body was completely stiff. This stiffness (rigor mortis) begins in all muscles 1–2 hours after death when the environmental temperature is approximately 75°F. The body will be in complete rigor in 10–12 hours and remain stiff for another 24–36 hours at the same environmental temperature. Heat speeds up the process and cold retards it. See next photo.

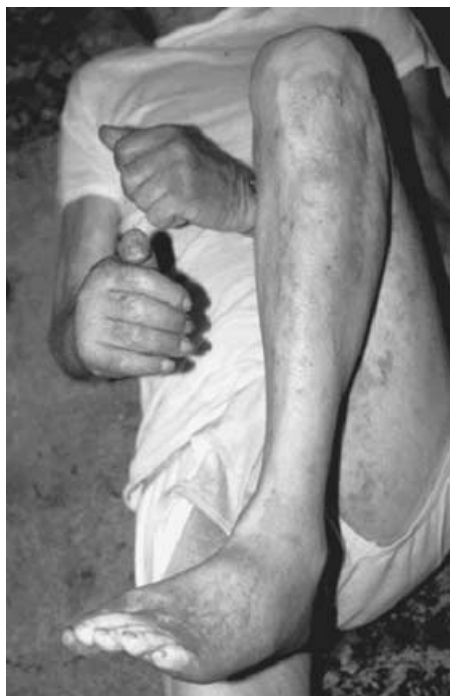

Figure 1.2 The man's knee remains bent after he is moved because the rigor mortis is still in a fixed position. If discovered in this position, the examiner would know the body had been moved.



Figure 1.3 Law enforcement first saw this man in bed with his arms “fixed” and suspended above his head. This proves he was in a different position prior to examination by law investigators.

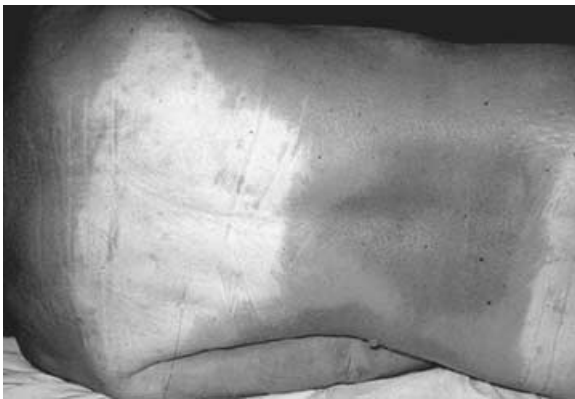

Figure 1.4 Livor mortis. Blood settles with gravity after a person dies. The blood becomes fixed in the dependent position in approximately 8–10 hours. Prior to fixation, the blood will redistribute to the new dependent location if the body is moved. The normal color of livor mortis (lividity) is purple. The cold, cyanide, and carbon monoxide can cause red lividity.

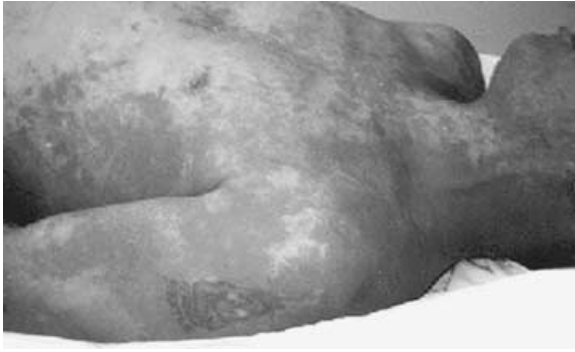

Figure 1.5 Lividity and congestion (buildup of blood) in the head, neck, and upper chest can give this splotchy pattern. This pattern is not indicative of a particular disease or traumatic entity.

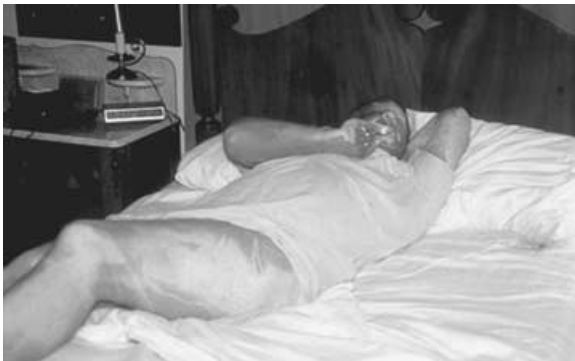

Figure 1.6 This man was discovered dead in bed. The pattern of livor mortis suggests the man had been moved after the livor mortis had fixed. See next photo.

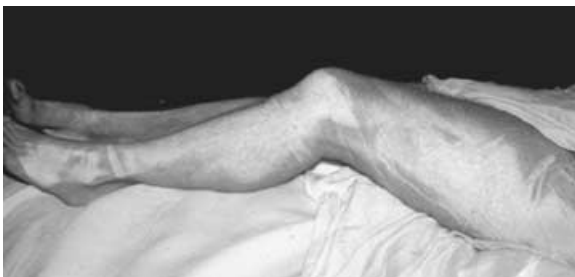

Figure 1.7 The pattern of bedding on the leg suggests the decedent was lying on the bed after death.

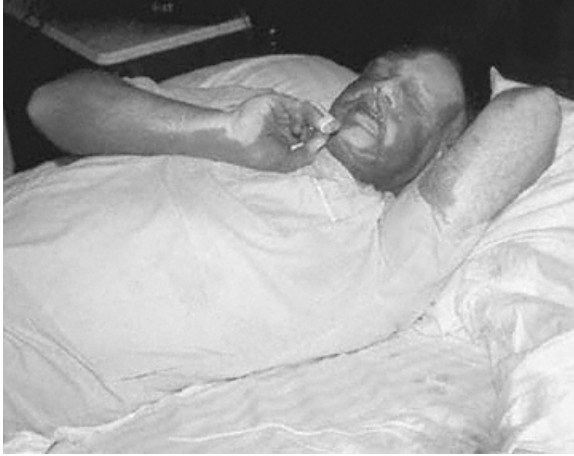

Figure 1.8 The lividity pattern is consistent with the man being on his face in the bed. Fluid stains (arrow) on the bed also show he had been moved.

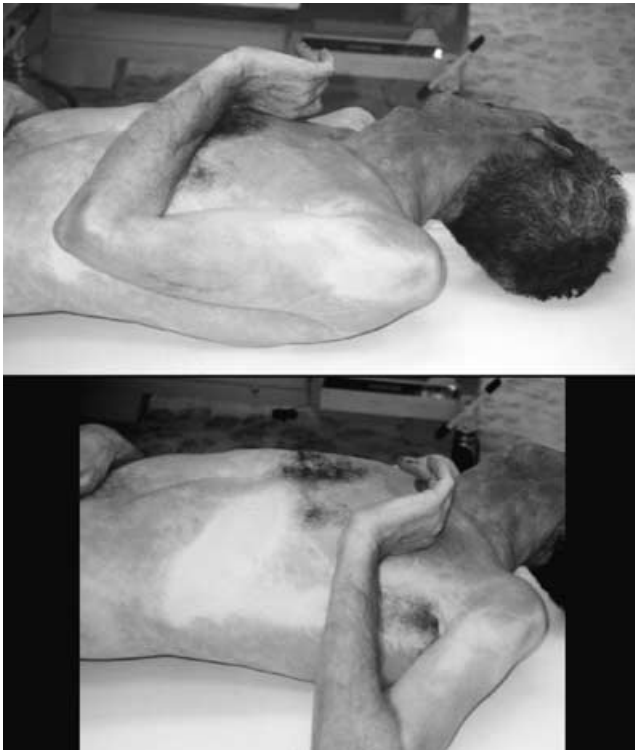

Figure 1.9 This man's arm was in complete rigor against his body. When the arm is moved, the absence of lividity is apparent where the arm was in contact with the skin.

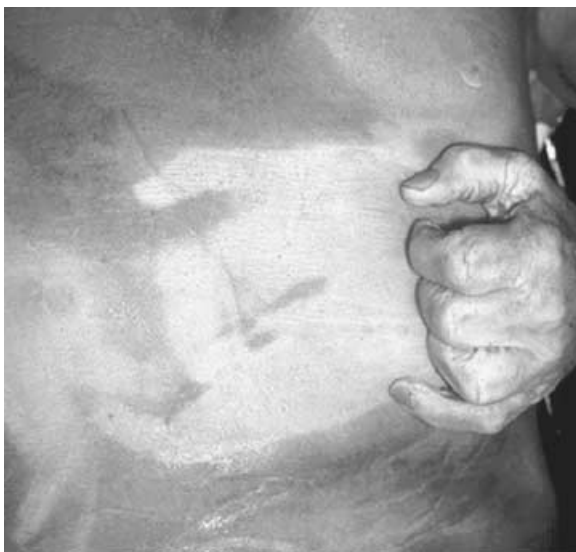

Figure 1.10 The livor mortis outlines the decedent's hand. This pattern will not go away since the lividity is fixed.

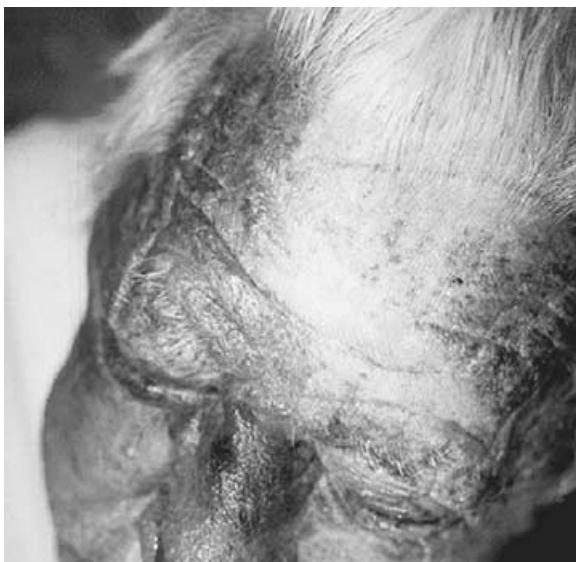

Figure 1.11 The pale mark on this man's forehead indicates he was resting on his head after death.



Figure 1.12 This man died after a brain hemorrhage. See next photo.

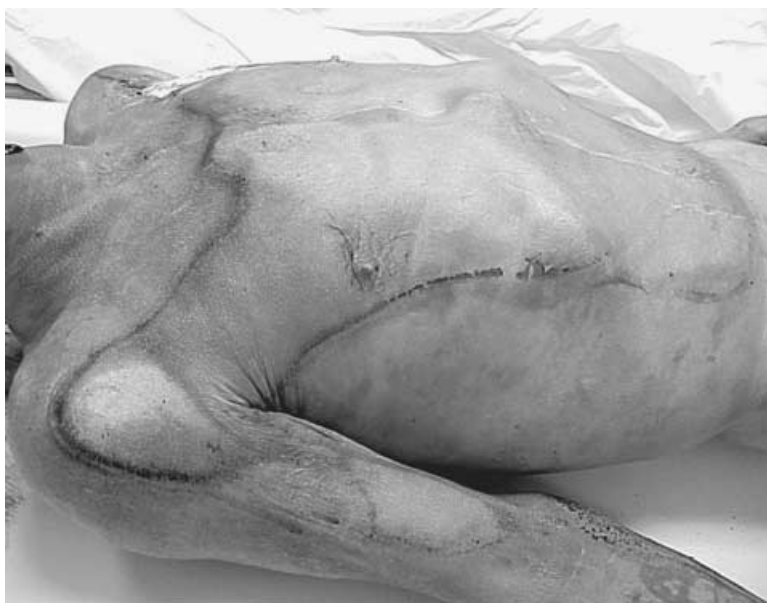

Figure 1.13 The anterior lividity with the pale areas is outlined in blood.

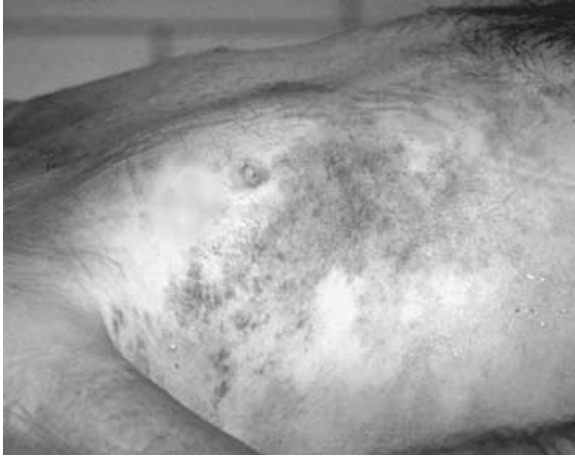


Figure 1.14 Occasionally, livor mortis may appear as an unusual pattern or look like an injury. This man was discovered at the bottom of some stairs. The pathologist can cut into the area to differentiate between livor mortis and injury. See next photo.

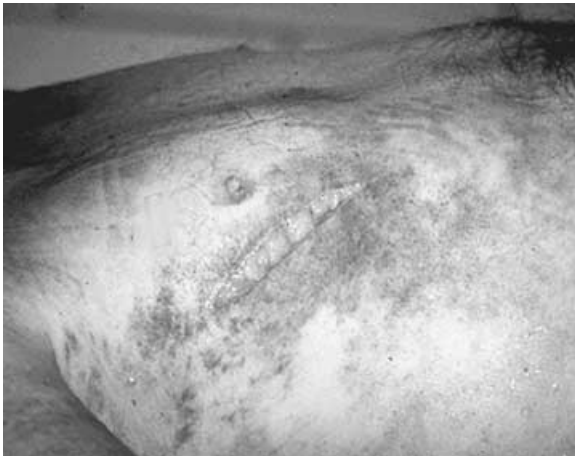

Figure 1.15 An incision into the area reveals only the yellow fat and no blood. This indicates the area is lividity and not an injury.

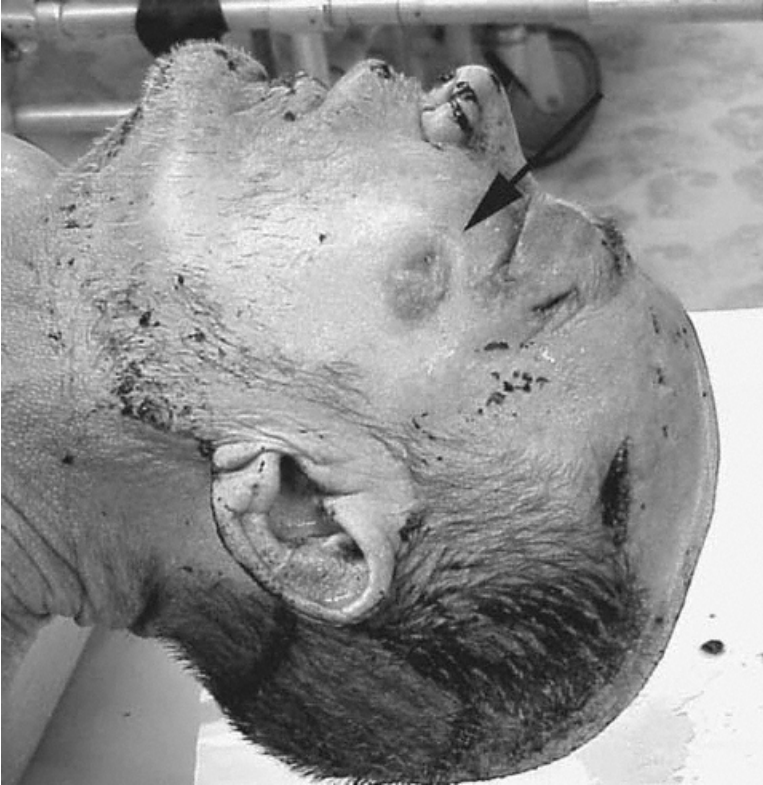

Figure 1.16 The pale mark on the left side of the face indicates that side of the face was against the floor.

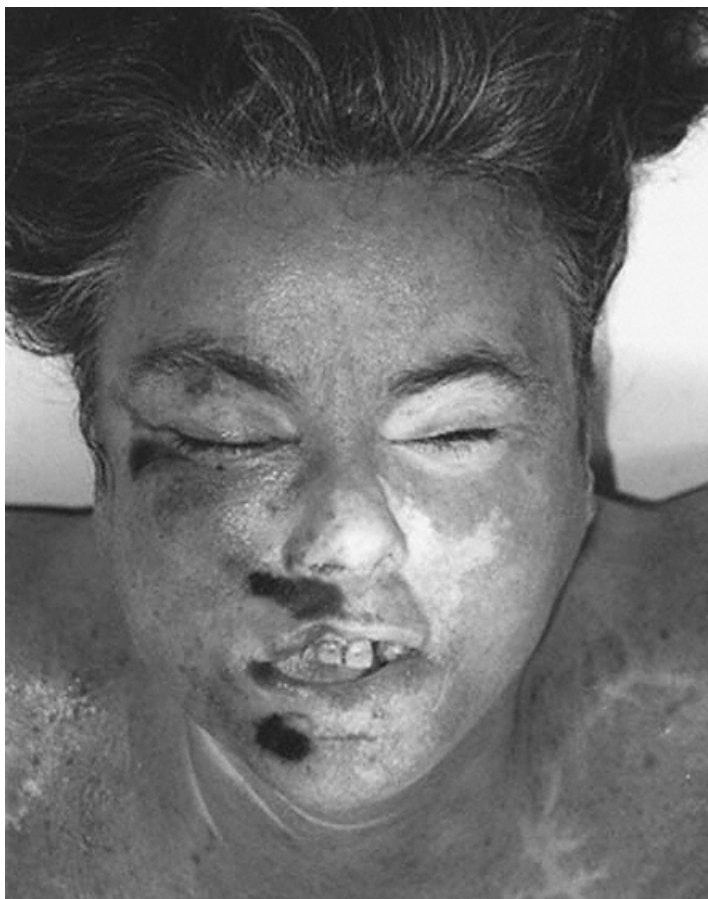

Figure 1.17 This woman was face down on the floor. She has insignificant abrasions from striking the floor after her sudden collapse. See next photo.

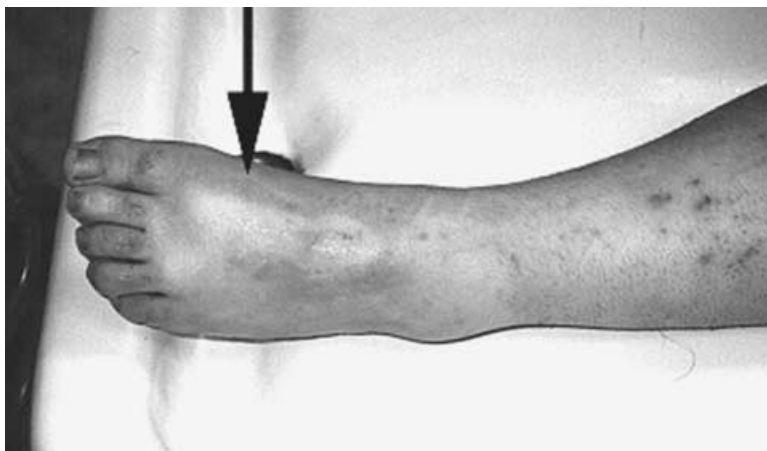


Figure 1.18 The paleness on the top of her foot also reveals she was face down on the floor.

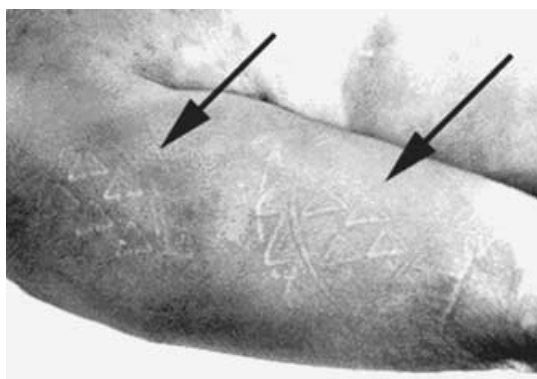


Figure 1.19 The arrows point to a shoe pattern on the decedent's arm. There were pale impressions and not bruises or scrapes. This indicates the person was lying against the shoes after death and not before.

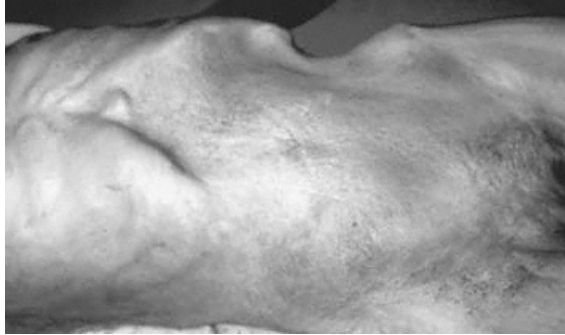

Figure 1.20 One of the first signs of decomposition is green discoloration of the skin, especially in the abdomen. Decompositional changes may appear within a few hours if the environmental temperature is high.

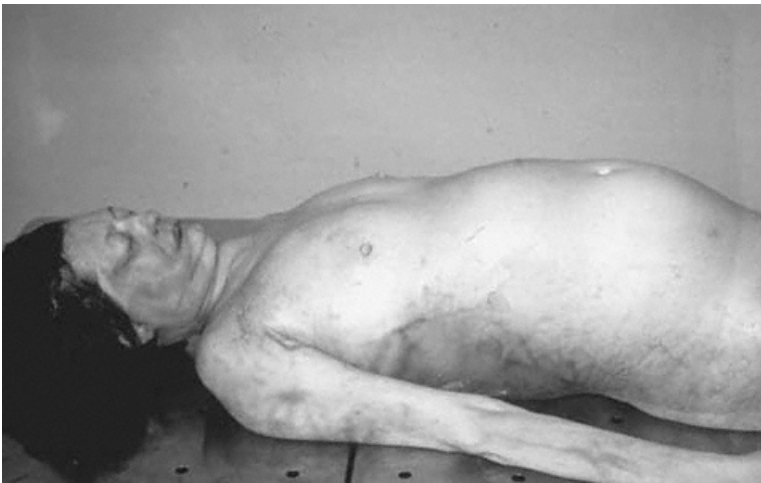

Figure 1.21 Slight bloating from beginning decomposition.

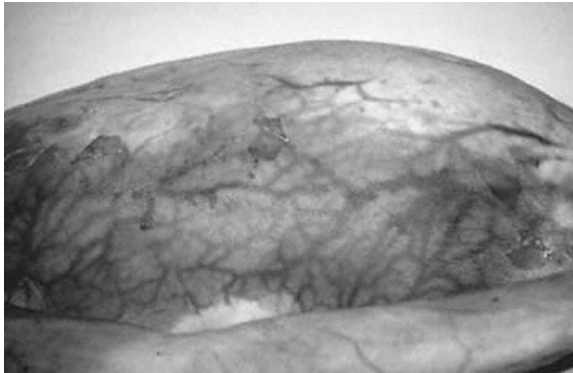


Figure 1.22 As decomposition progresses, the body swells (bloats) from bacterial gas formation and there is skin slippage and subcutaneous marbling (the outlines of the blood vessels under the skin).

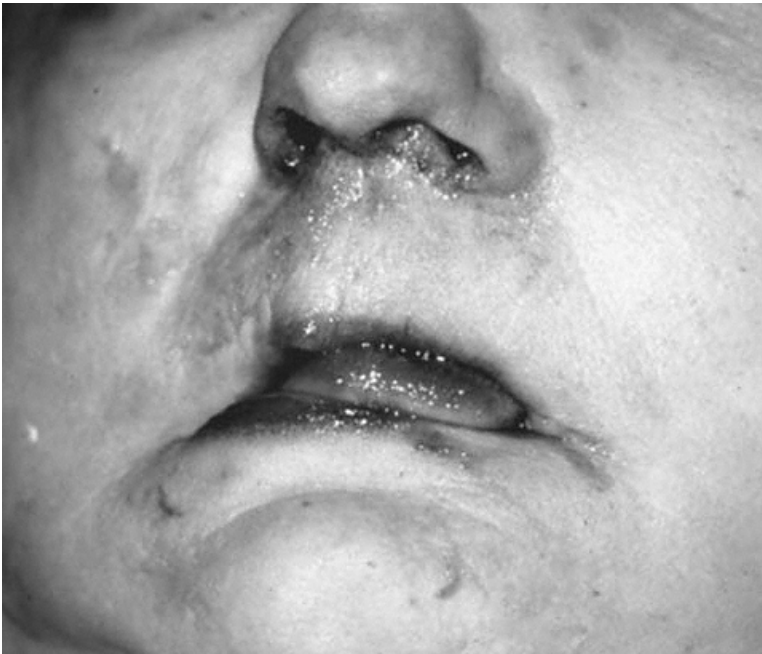

Figure 1.23 Drying artifacts of the nose and mouth. This should not be considered suspicious.

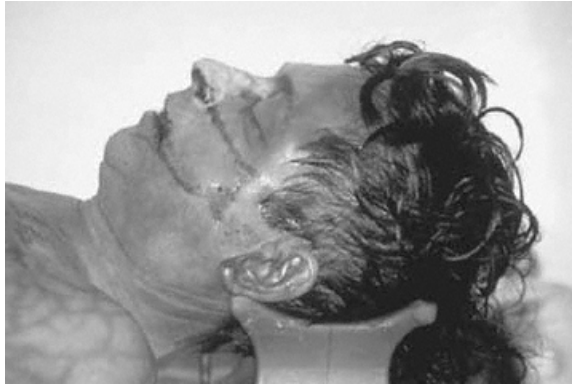

Figure 1.24 Internal pressure occurs on the internal organs when gas develops. Pressure pushes bloody fluid out the nose and mouth (purging). This should not be confused with trauma to the nose and mouth.

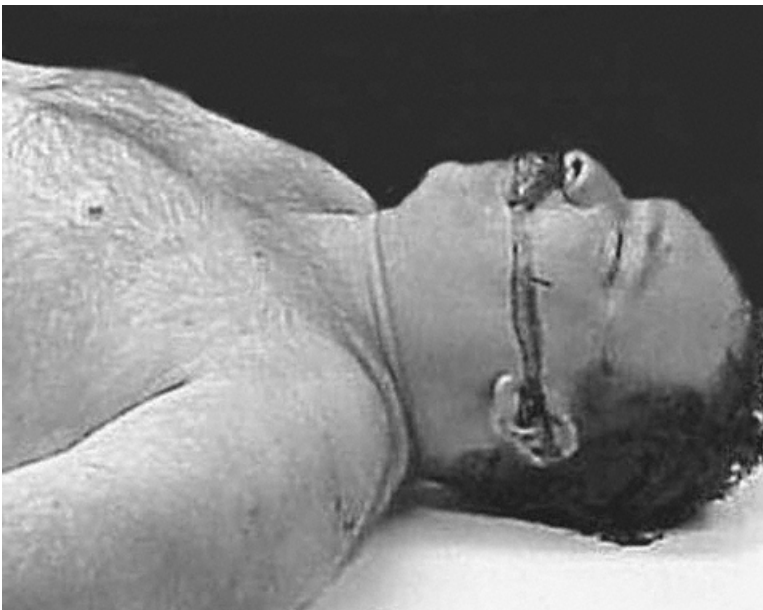

Figure 1.25 Another example of purging in beginning decomposition.

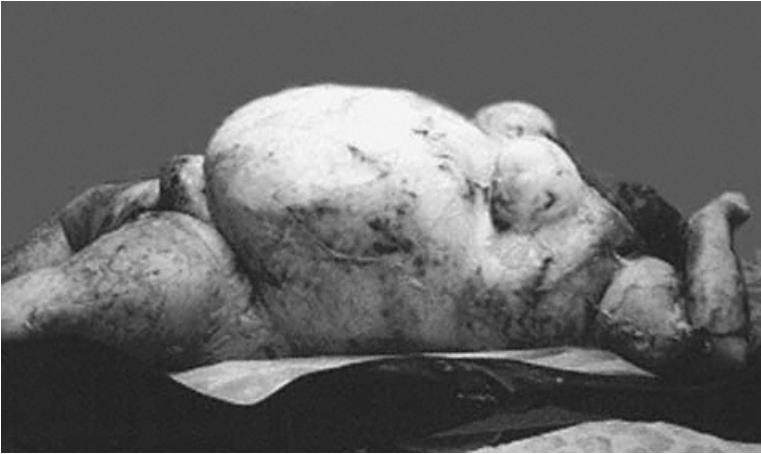

Figure 1.26 Marked bloating and skin discoloration after a couple of days in a warm house.

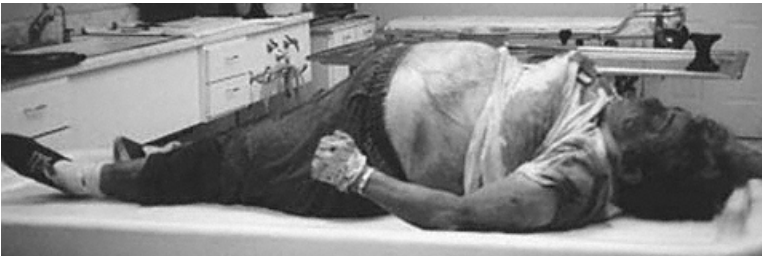

Figure 1.27 This lady was discovered dead near her garden, approximately 12 hours after she was last seen during July. See next photo.

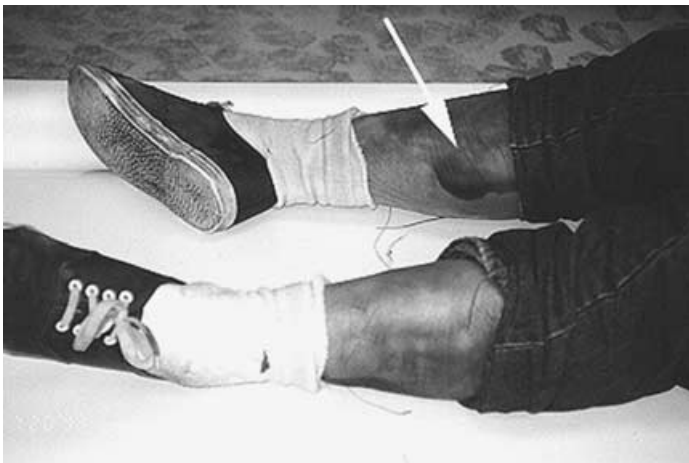

Figure 1.28 Fluid-filled blister (arrow) of decomposition.

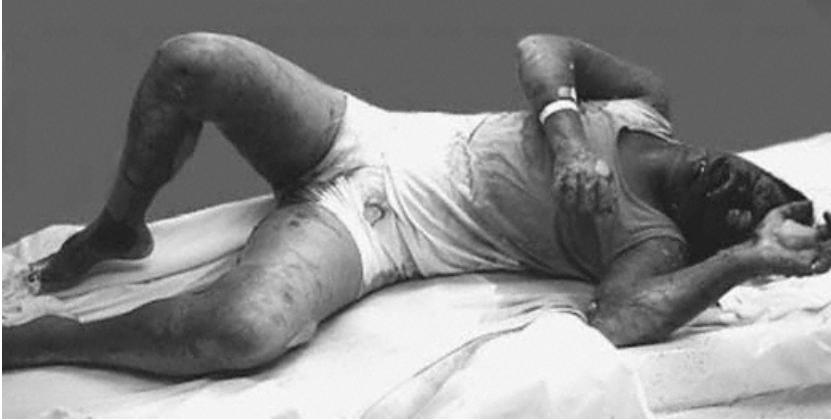

Figure 1.29 This woman is decomposing while she is still in rigor. The presence of rigor is more important than the decomposition in estimating the postmortem interval. See next photo.

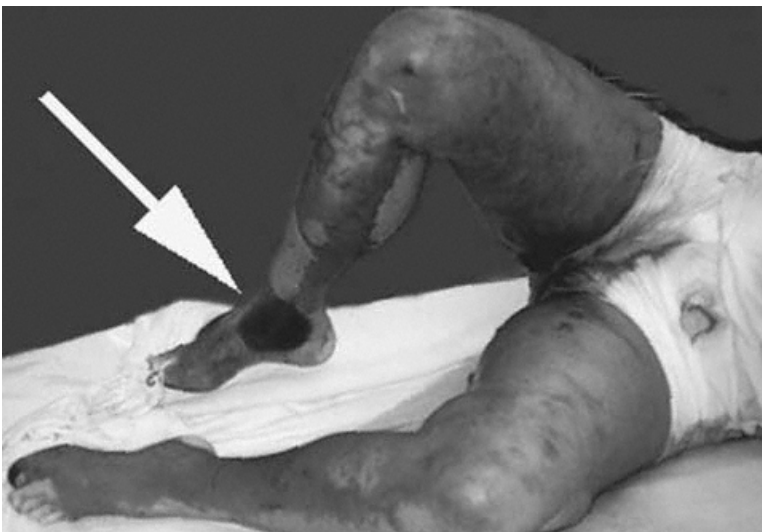


Figure 1.30 She also has fluid-filled blisters that should not be confused with thermal injuries.

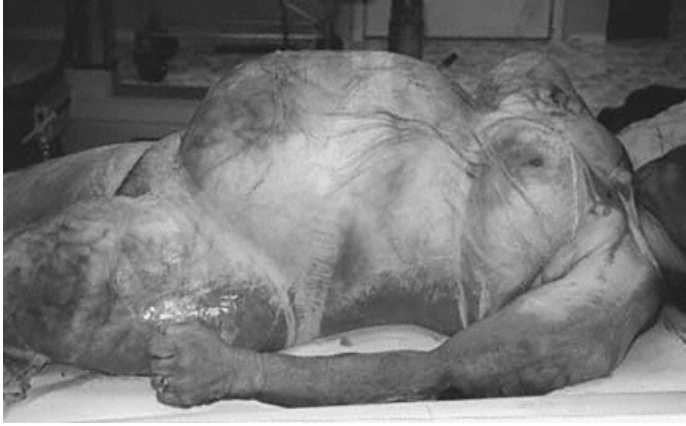

Figure 1.31 Marked skin slippage with slight to moderate decomposition.

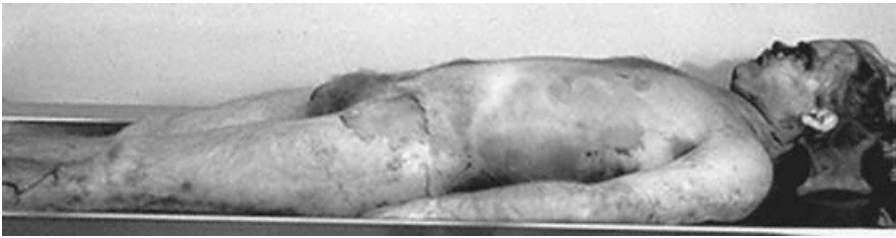

Figure 1.32 Bodies may not swell much when they are in hot and dry climates. The skin slippage may also be dry. See next photo.

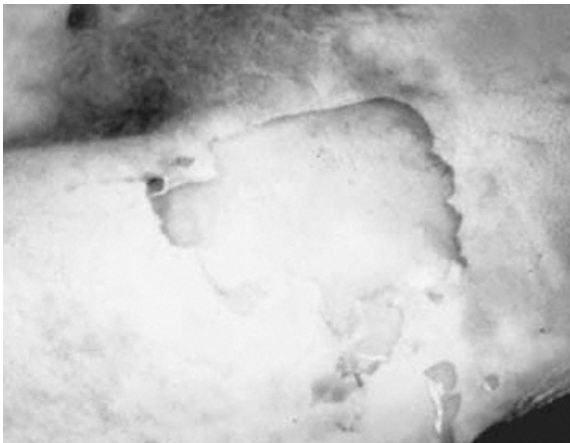


Figure 1.33 The skin slippage on the man's hip is dry, not wet and slippery as is usually seen.

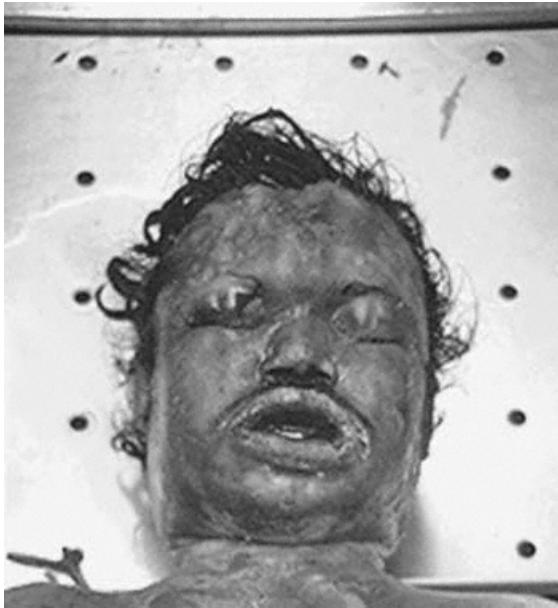

Figure 1.34 This man was 21, thin, and white. He was discovered in a river 4–5 days after he was killed in the summertime. Decomposition can cause the facial features to change and the hair to slip off. Visual identification may be difficult when such changes occur.

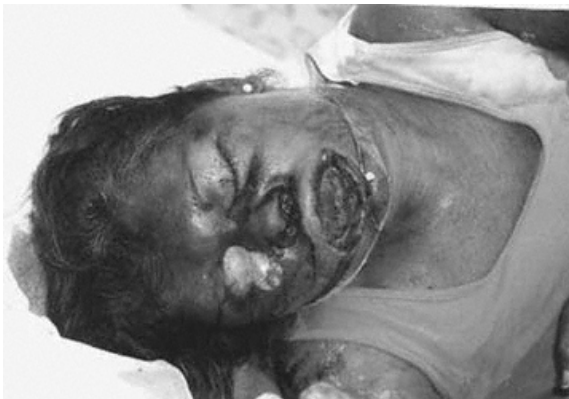

Figure 1.35 The facial features begin to change as swelling occurs during decomposition.

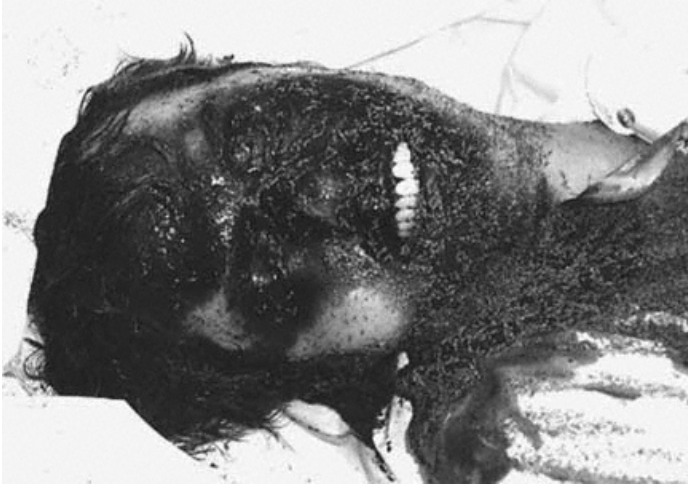

Figure 1.36 Marked decomposition of face and abundant maggots. The rest of the body was only slightly decomposed. He was face down on the ground. Maggots accumulate more in areas where there are injuries.



Figure 1.37 This 22-year-old white man was found in the woods on a hot summer day five days after he died. The body is markedly swollen and discolored. Initially, he was mistaken for an African-American man.

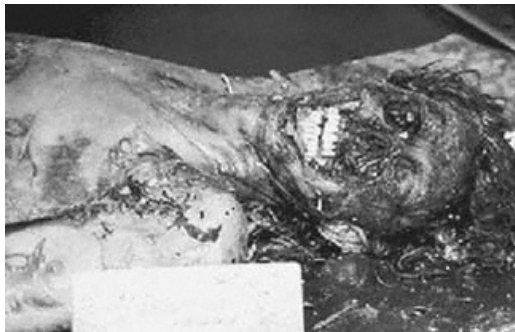

Figure 1.38 Three weeks in the winter under a brush pile caused this man's decompositional changes. The head area is more decomposed than the rest of the body because he had been shot multiple times there.

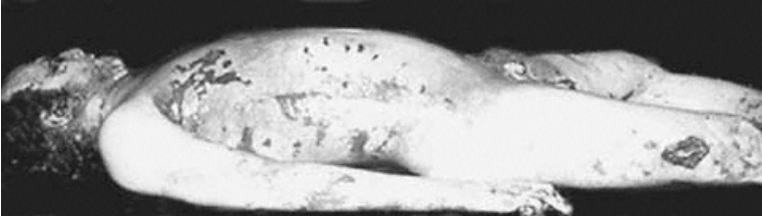


Figure 1.39 Except for a few injuries, this man's body is in relatively good shape. He was identified visually. He had been in the water for at least three weeks during February.

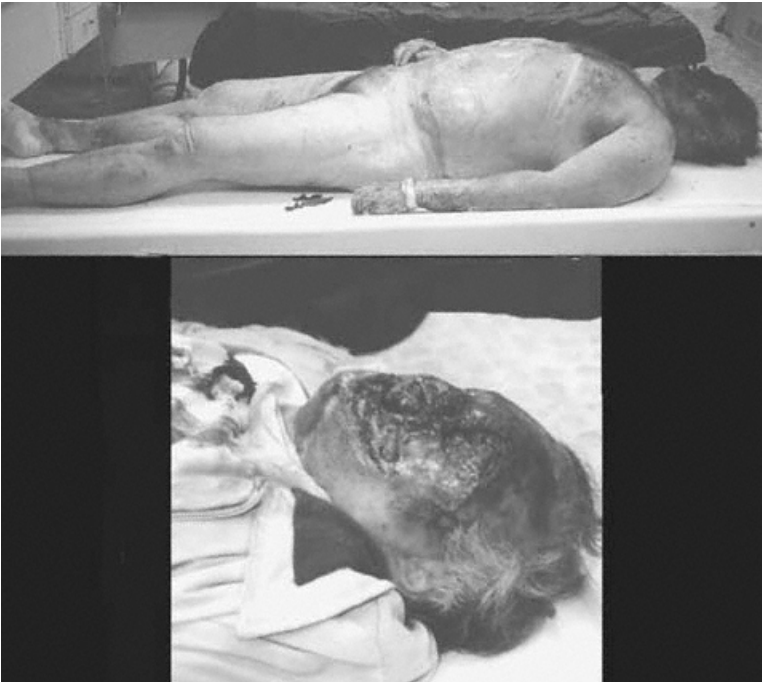


Figure 1.40 More decompositional changes of the face, because he was face down (similar to 1.36).

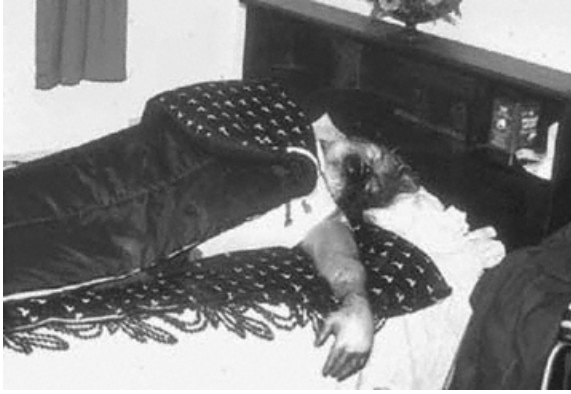

Figure 1.41 This is another example of asymmetrical decomposition. The exposed head is much more decomposed than the rest of the body within the sleeping bag. Covered areas prevent decomposition changes from occurring as quickly as exposed parts of the body.

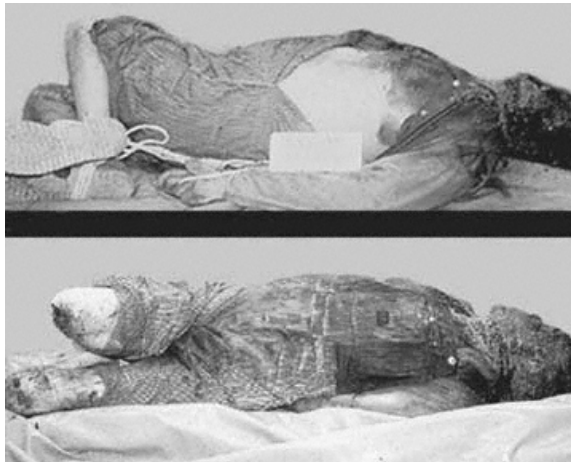


Figure 1.42 This man was found on the side of the road two days after he was strangled and beaten in the head. He was also covered with a blanket. See next photo.

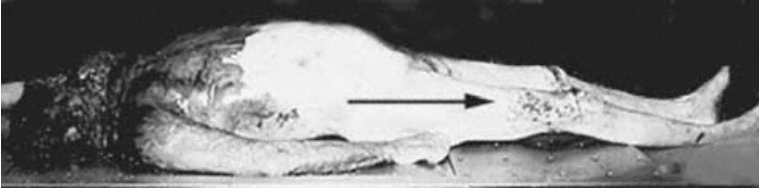


Figure 1.43 His body was much more decomposed in the head region where he was injured and less where he was clothed and covered with the blanket. This asymmetrical decomposition is commonly seen when insects and flies are attracted to the blood in the injured areas. Estimating time of death must be done with the least decomposed areas. The arrow points to postmortem insect activity (anthropophagia).

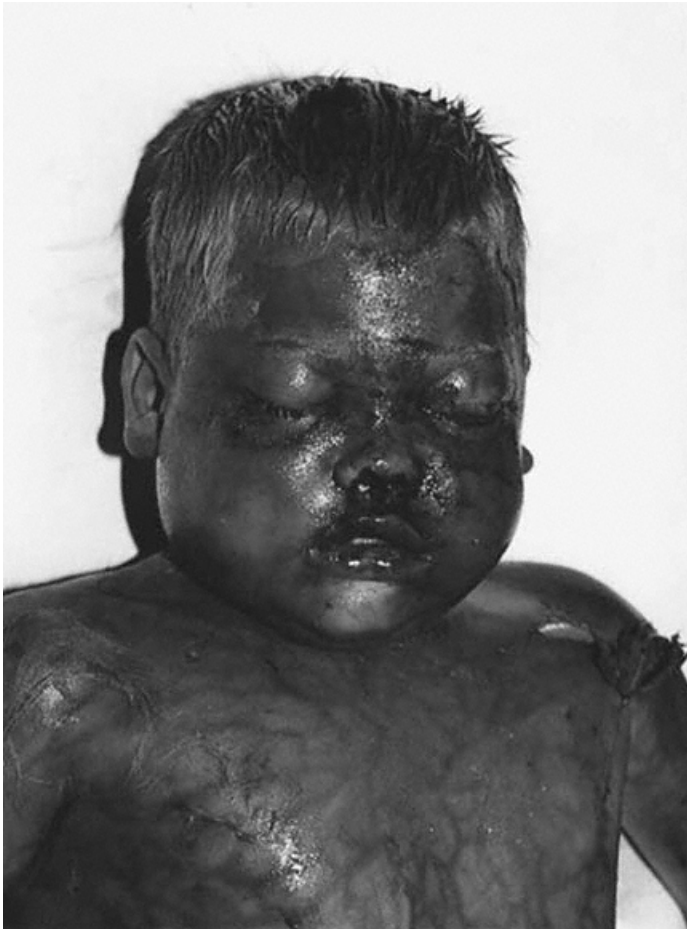

Figure 1.44 This boy was one of four family members who drowned after his father drove their car off the road and turned upside down in a river. They were found two days later. See next photo.

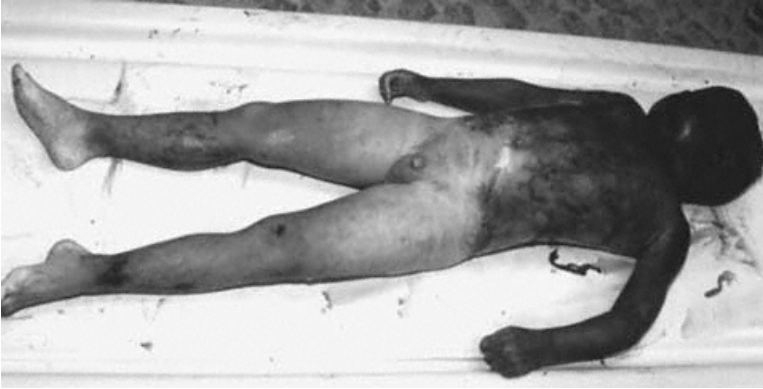

Figure 1.45 Because he was belted in upside down in the car, the upper part of his body is more decomposed than the lower part. See next photo.

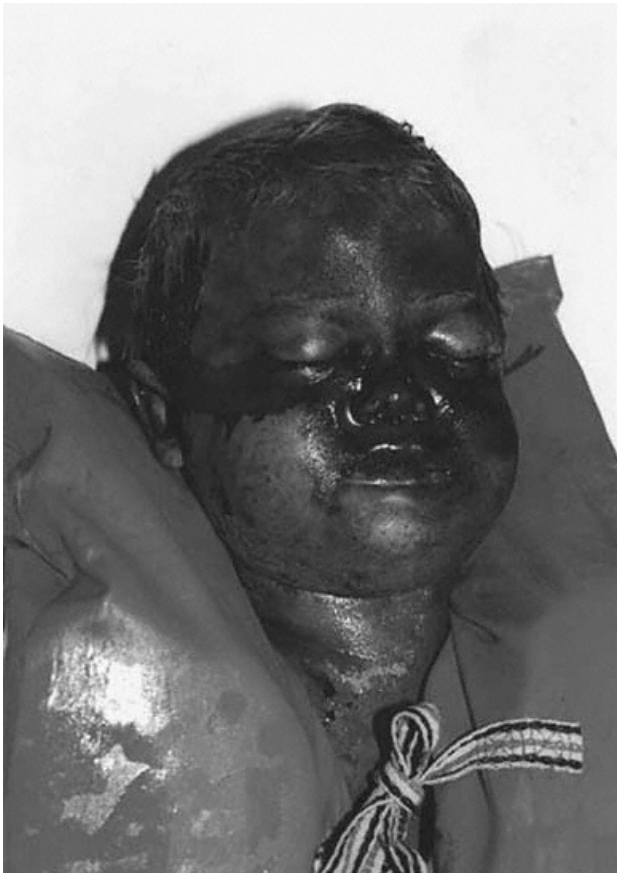

Figure 1.46 His younger brother was wearing a life jacket and was also belted in the seat. See next photo.

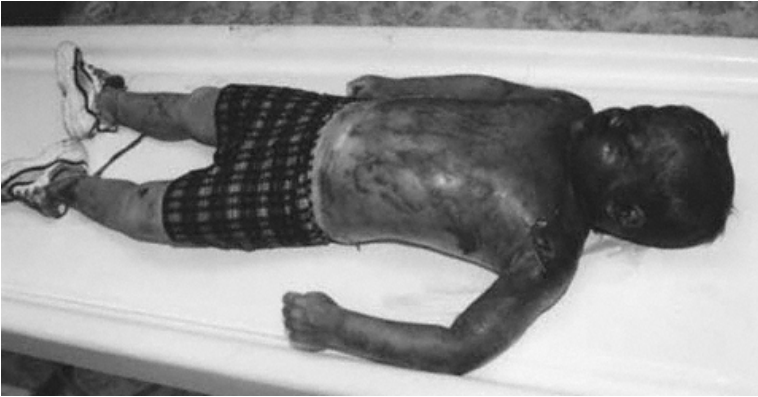

Figure 1.47 The difference between his upper and lower parts are not as distinct as his brother. See next photo.

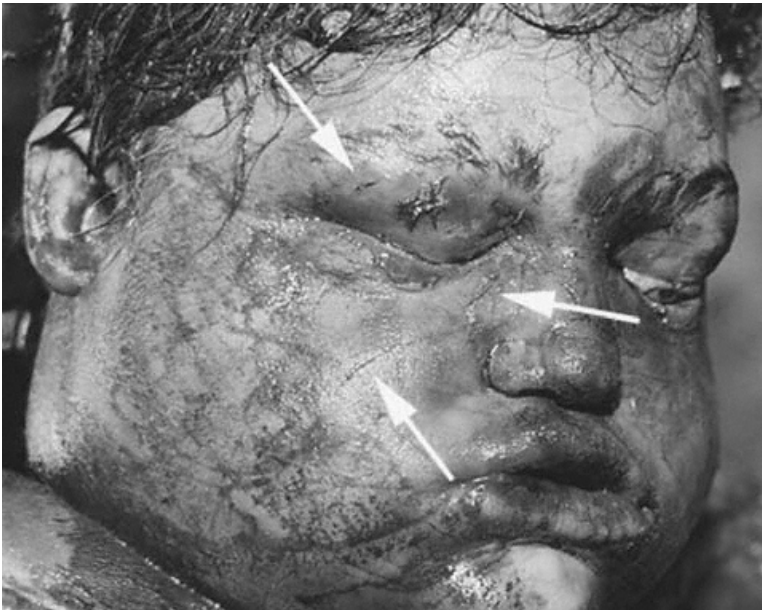

Figure 1.48 Their mother was decomposed similarly to the boys, however, she also had facial cuts from glass. See next photo.

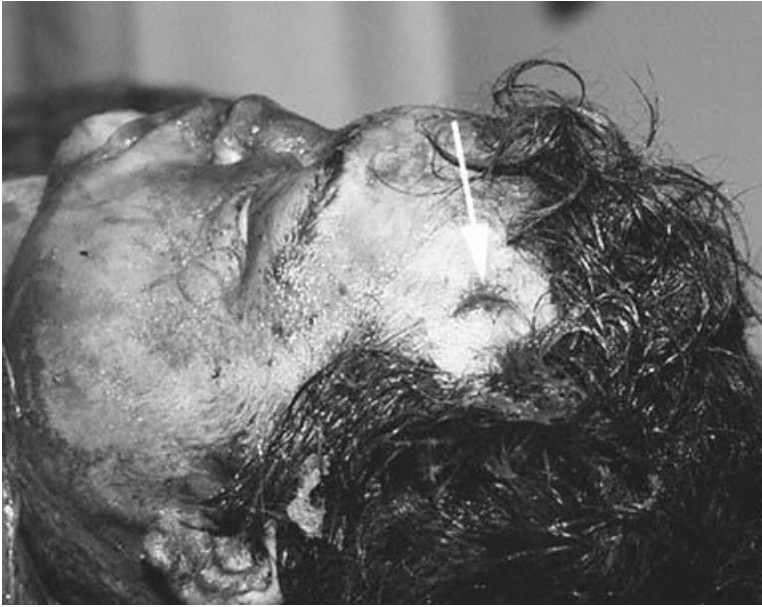

Figure 1.49 She also had a laceration of the forehead.

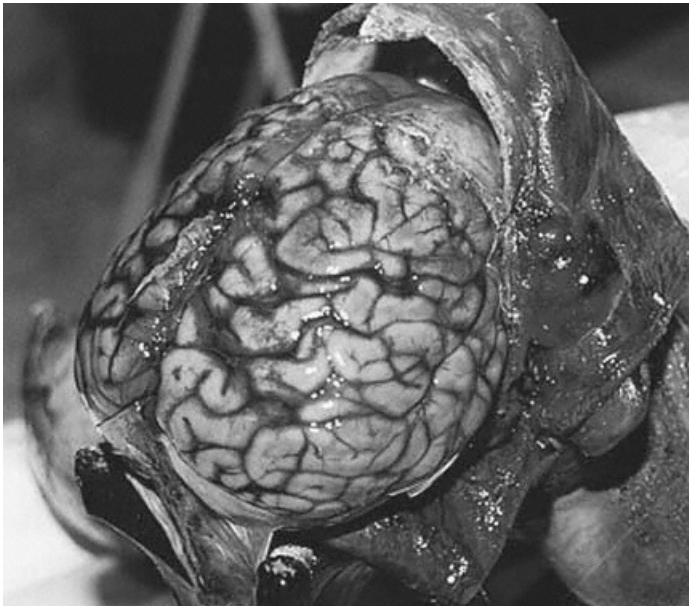

Figure 1.50 Organs begin to soften as decomposition occurs. This brain is only slightly decomposed. Eventually, decomposition will cause the brain to flow out of the skull in an amorphous mass.



Figure 1.51 The next series of photos are of a man shot in the back of the head and buried. He was discovered six months after burial. See next photo.

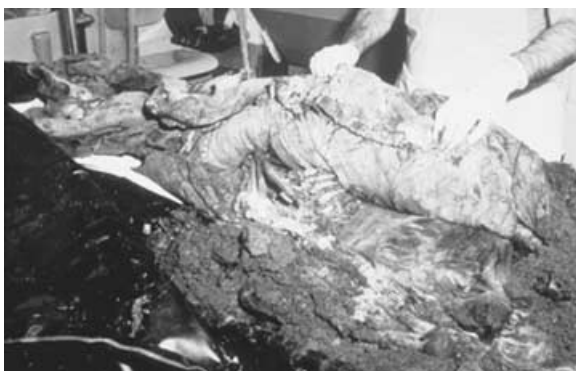

Figure 1.52 Much of the surrounding dirt accompanied the body. The blanket wrapping the body was carefully removed. The remains and the dirt had already been X-rayed. No bullets were discovered.



Figure 1.53 The next of kin identified the T-shirt. It had the distinctive phrase "Kiss my Grits." See next photo.

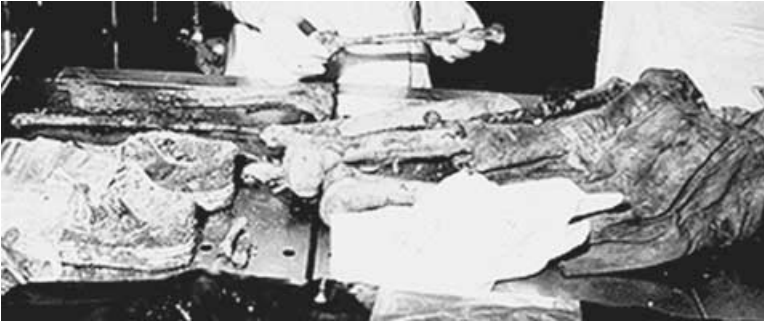

Figure 1.54 The skeleton was complete except for the head. Many of the facial fragments were lost at the time of the shooting. The man was wearing red shoes, shorts, and a shirt, which were used in the identification. See next photo.

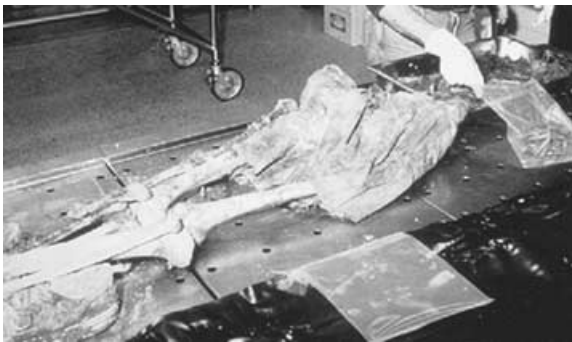
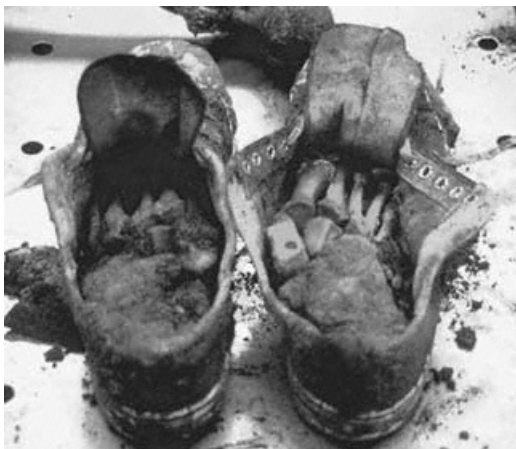
Figure 1.55 There was no soft tissue remaining. A dentist was asked to look through all of the bone fragments of the face and head in order to find some teeth for identification. He was unsuccessful. See next photo.



x

Figure 1.56 The bones of the feet were still in the red sport shoes.

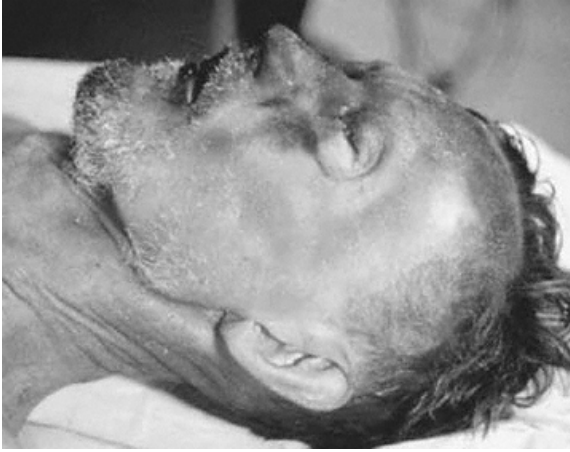

Figure 1.57 Mummification. The skin dries out and turns leathery. This man's head mummified within two days because his head was next to a heater. His head will not decomposed further due to the mummification. See next photo.

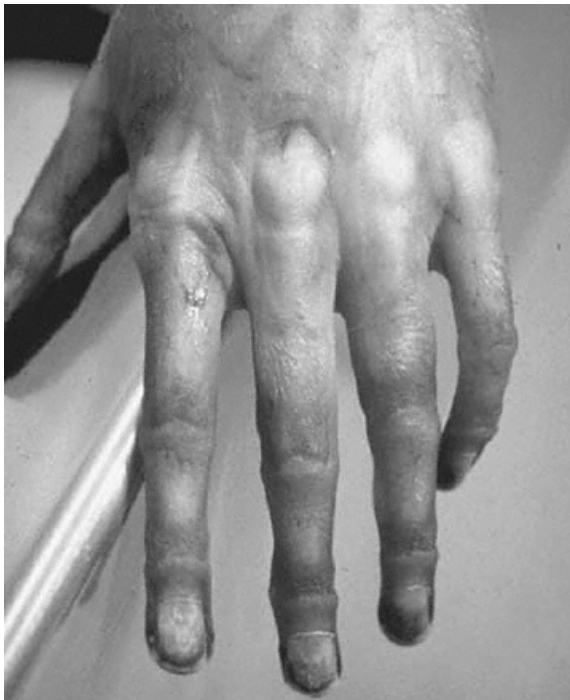

Figure 1.58 His hands had also mummified.

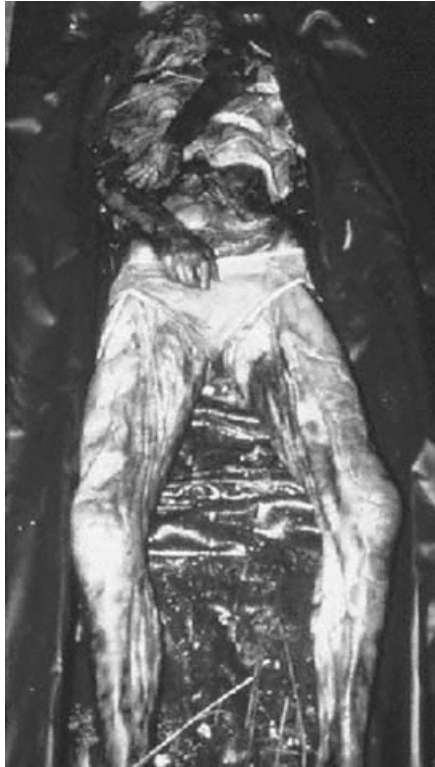

Figure 1.59 These remains were completely mummified in approximately six weeks during the summer months.



Figure 1.60 Adipocere. A clothed body wrapped in a U-Haul blanket was discovered at the edge of a lake. See next photo.

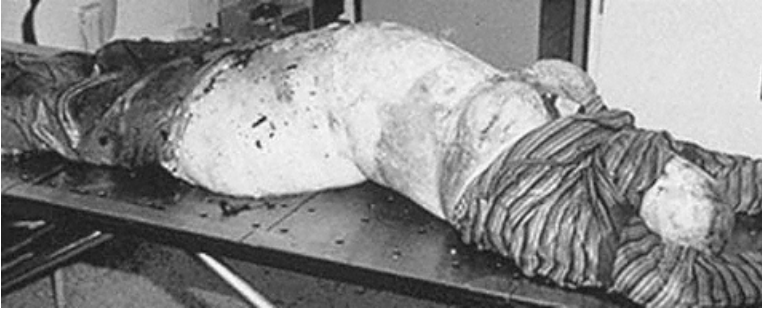


Figure 1.61 The body was still white and originally thought by law enforcement to not be very decomposed. They thought the body had been in the water about a week. See next photo.

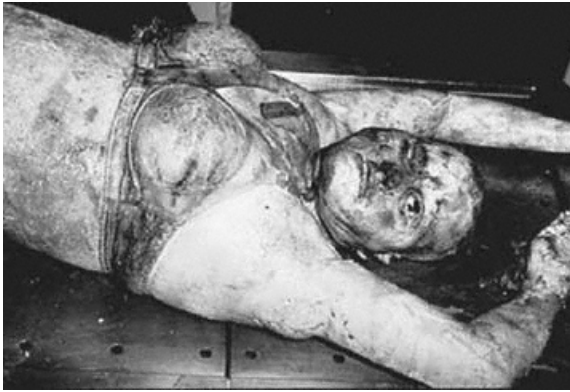

Figure 1.62 Even though she had been in the cold water for over ten months, the sheriff visually identified her. See next photo.

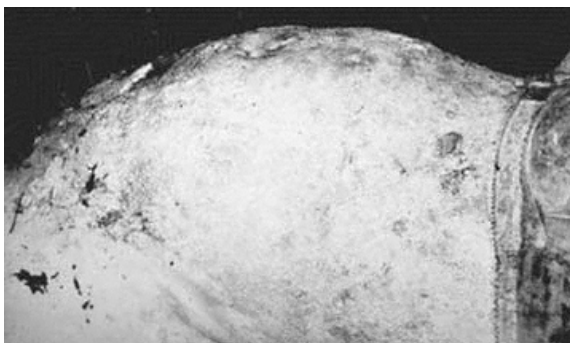

Figure 1.63 Upon closer examination, the skin appeared to be thickened with the superficial layers of the skin missing. This change is called adipocere. The soft tissue turns into a soap-like substance (saponification). This occurs in cold wet conditions. Once the change occurs, it will remain for years. See next photo.

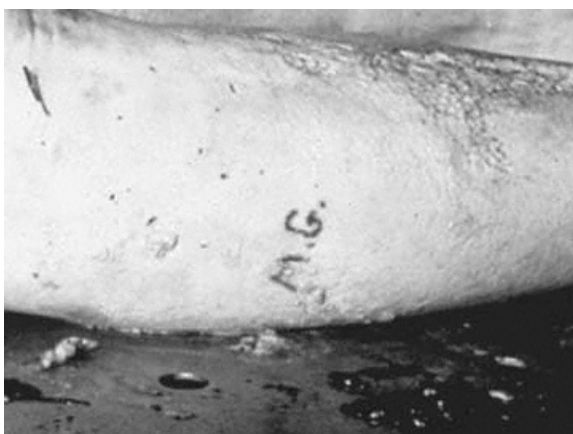

Figure 1.64 She was also identified by numerous tattoos. See next photo.

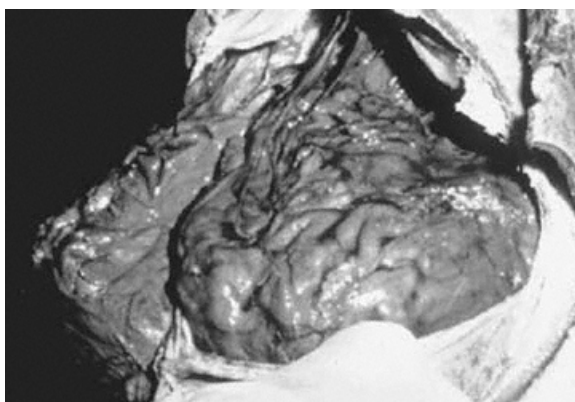


Figure 1.65 The internal organs were in remarkably good condition given the time in the water. This photograph of the brain shows that it was still in good enough condition to be examined for evidence of trauma.

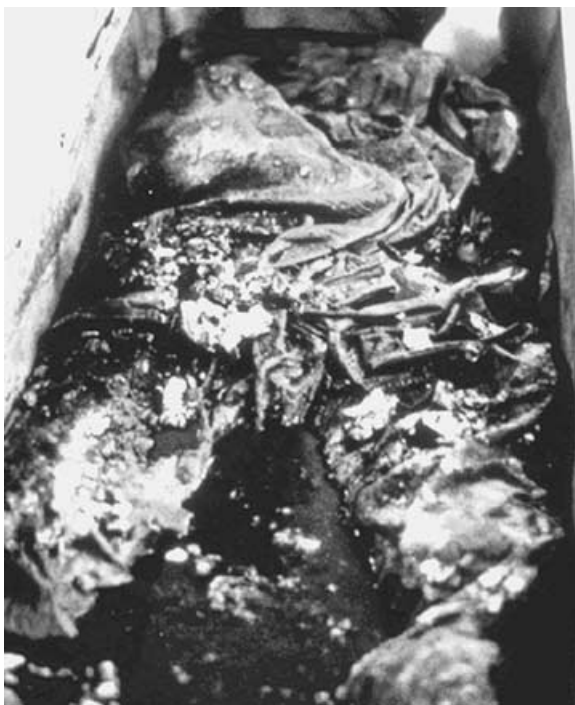

Figure 1.66 This case is another example of adipocere. The body was buried for more than two years in a casket filled with water. See next photo.

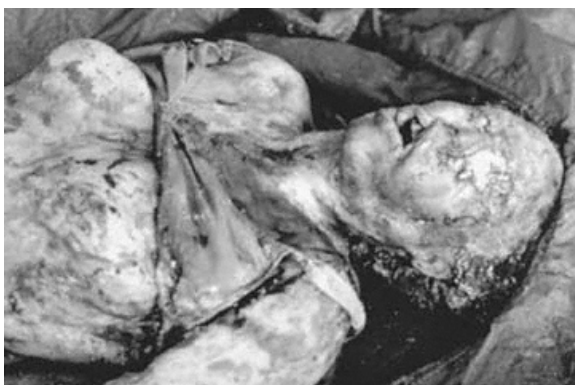

Figure 1.67 The remains are much less preserved than in the previous case. An examination could be made; however, the results were not as good as hoped.

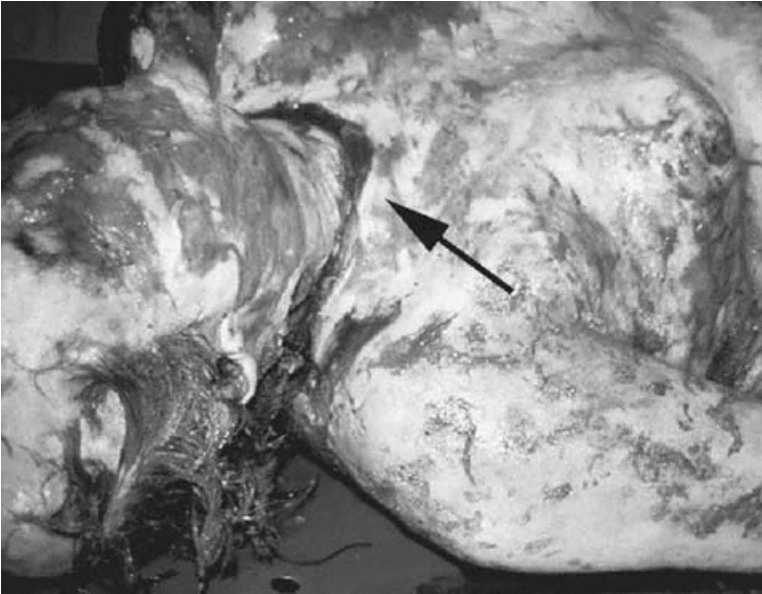


Figure 1.68a This woman was in cold water for approximately three months. Adipocere was only beginning. Adipocere change usually takes months before it is well developed. The mark on the neck is from a cable (tied to a concrete block) which aided in sinking the body.



Figure 1.68b This woman floated over 100 miles down the Missouri River. She had been missing for over two months. Her body was in the beginning stages of adipocere formation.



Figure 1.69 This man had been embalmed and buried for over three years. See next photo.

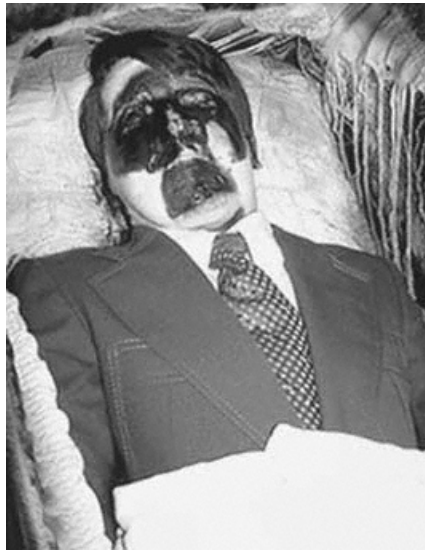

Figure 1.70 Aside from the mold, the body was well preserved. See next photo.

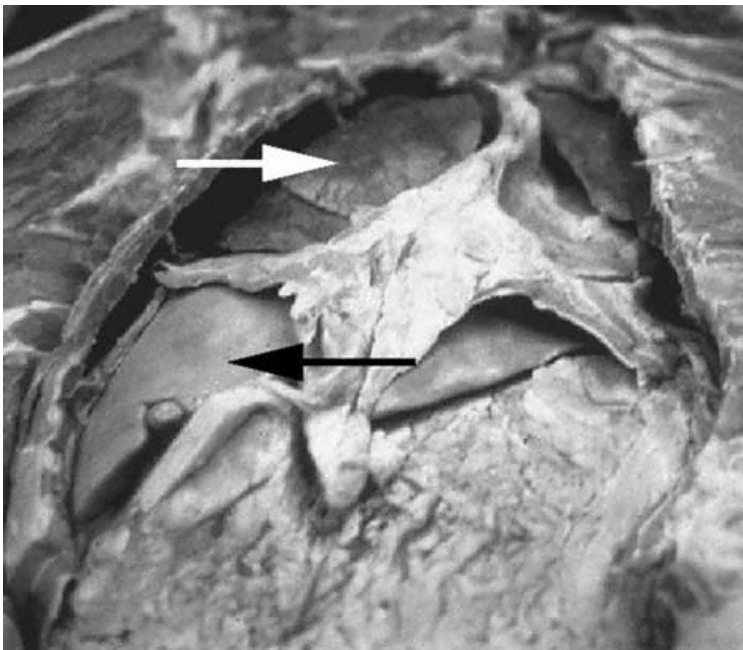


Figure 1.71 The internal organs were in very good condition and could be easily evaluated. The white arrow points to the right lung and the black arrow points to the liver.

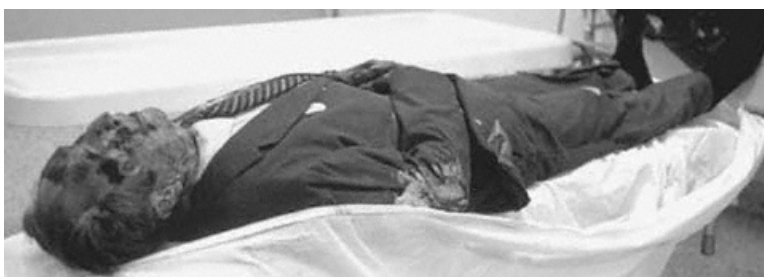

Figure 1.72 This man's body was disinterred because a faulty heart valve was thought to be the cause of his death. See next photo.

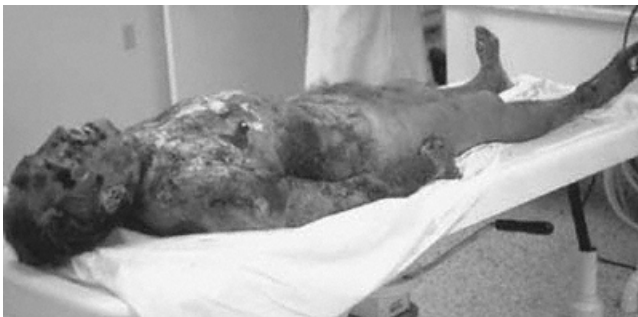

Figure 1.73 The body had undergone moderate change with mold on the external surface and internal organ softening and discoloration. See next photo.

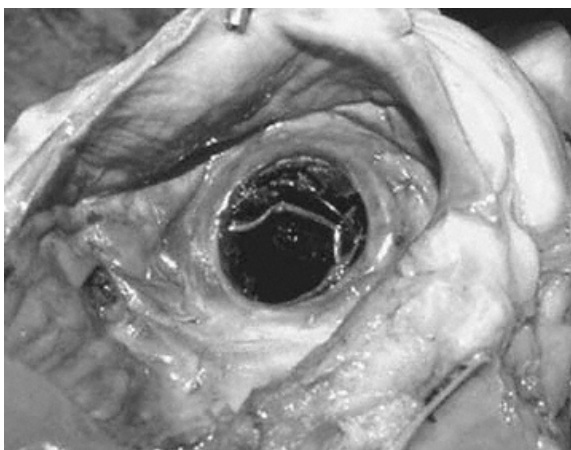

Figure 1.74 The heart valve could easily be located and evaluated. In this case, the valve did not malfunction; however, it was damaged from the trocarring performed during the embalming process.

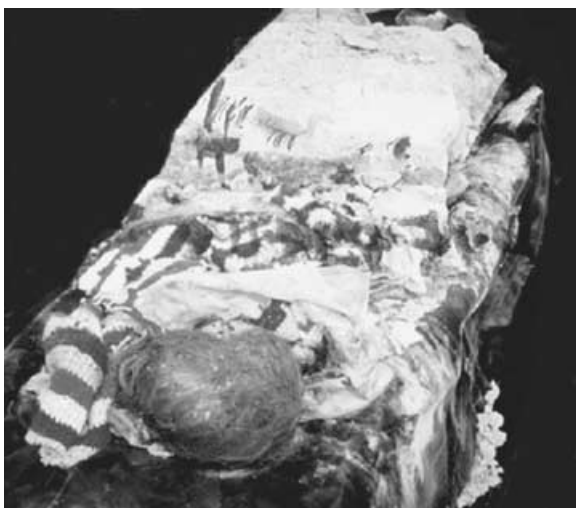


Figure 1.75 This woman's body was placed in a steel box, filled with concrete, and buried under the house. The concrete did not totally encase the body because her back was lying on the bottom of the box. She was found approximately 18 months after death. See next photo.




Figure 1.76 The concrete was over 7" thick. See next photo.



Figure 1.77a The body had markedly decomposed while in the concrete for almost two years. No cause of death could be proven. There were no fractures. The woman was thought to have been strangled.



Figure 1.77b A woman was abducted, killed, and buried here in the woods. See next photo.



Figure 1.78 After ten days in the ground, the body was in relatively good condition. See next photo.

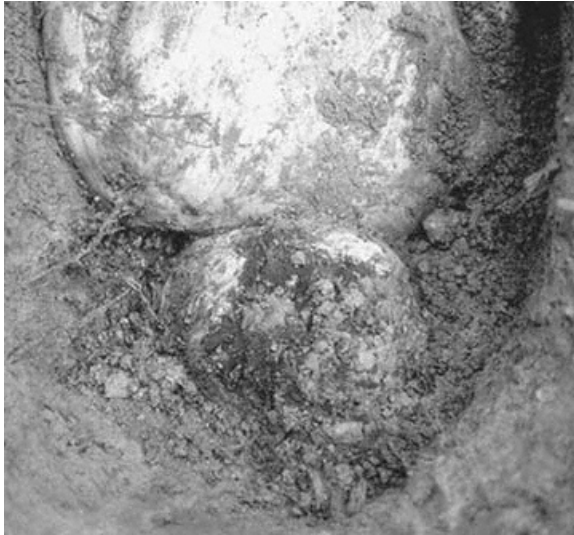

Figure 1.79 There was obvious trauma to the head. The body was transported directly to the morgue and placed in refrigeration. See next photo.

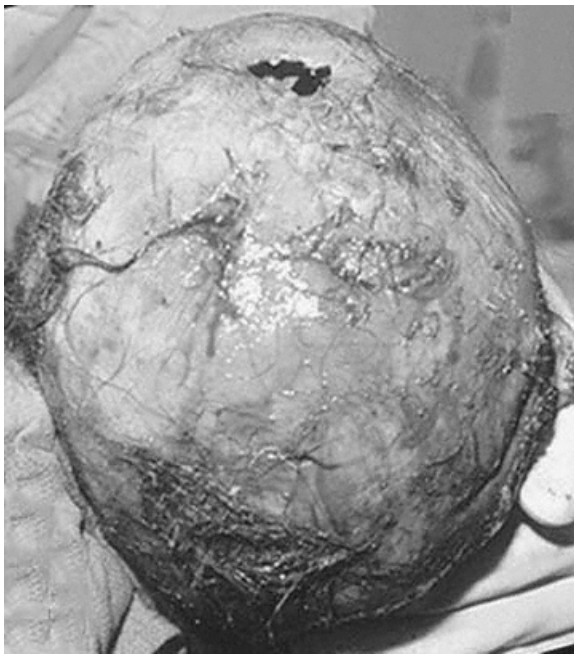

Figure 1.80 This is the top of her head the next day at autopsy. There were marked decompositional changes by the time the autopsy was performed. Bodies can change significantly from the time they are discovered until the examination.

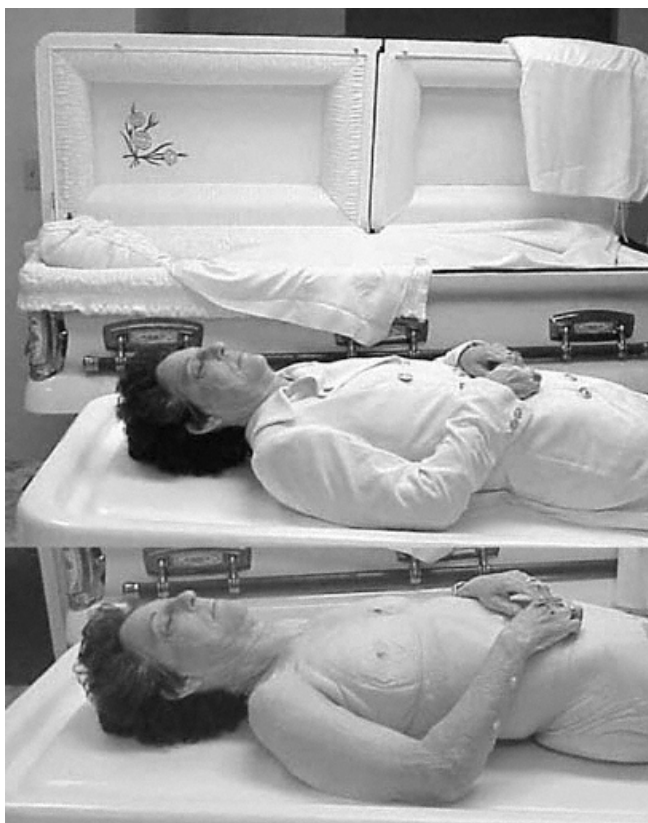

Figure 1.81 This woman was buried for almost a year. See next photo.

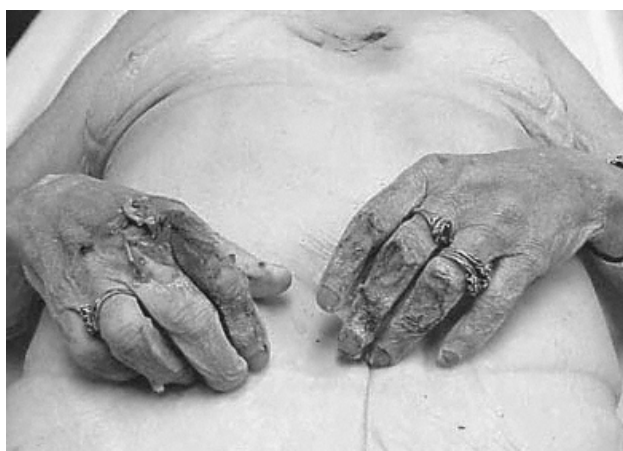

Figure 1.82 Her body was in remarkably good condition except for some mold and skin slippage on her hands.

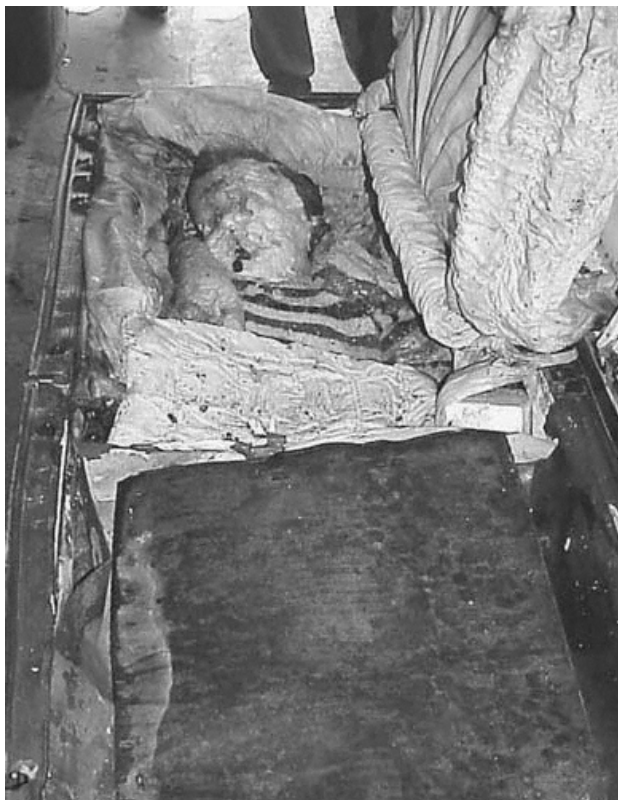

Figure 1.83 A two year old was disinterred nine years after burial. He was not autopsied prior to burial. His babysitter reported he had fallen down some stairs. Her story was accepted, even though there was a fracture of the skull and retinal hemorrhages. See next photo.



Figure 1.84 There were marked decompositional changes. See next photo.

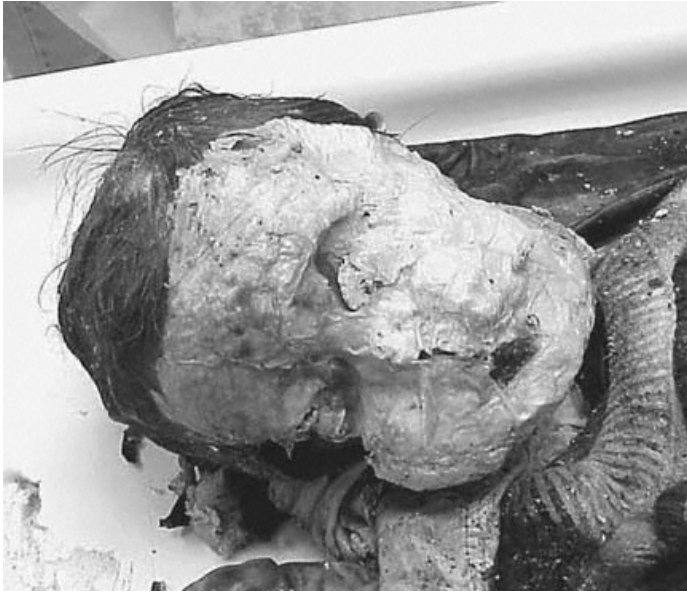

Figure 1.85 The face had a putty-like consistency from adipocere change. There were no visible external injuries. See next photo.

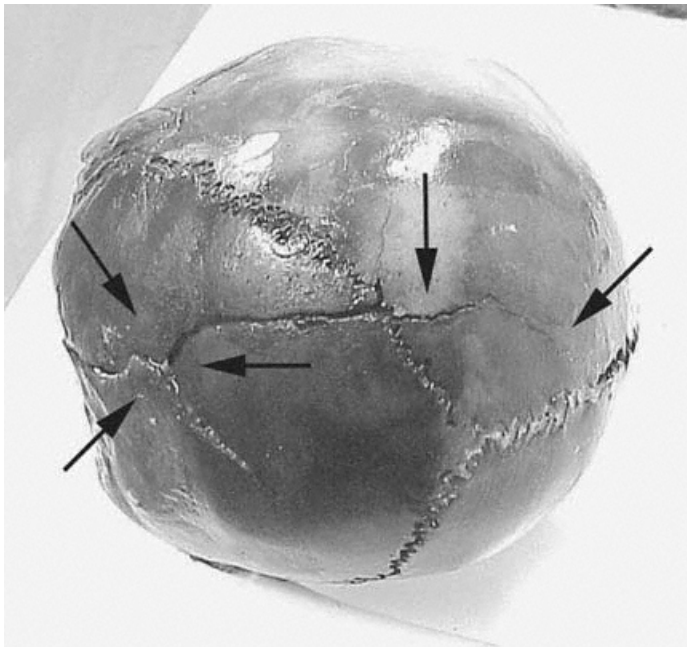


Figure 1.86 A depressed skull fracture (arrows) in the posterior skull extended toward the front. This is inconsistent with a fall. When confronted, the babysitter admitted striking the child.

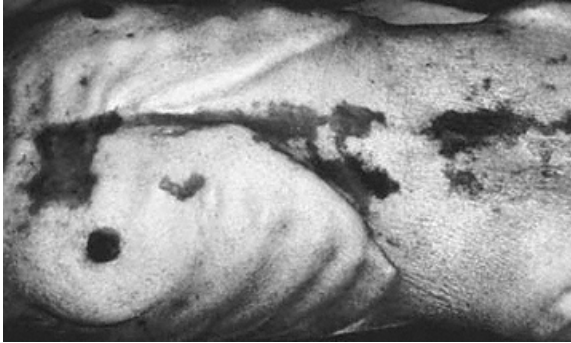

Figure 1.87 Roaches caused these abraded lesions after death. This is called anthropophagia. See next photo.

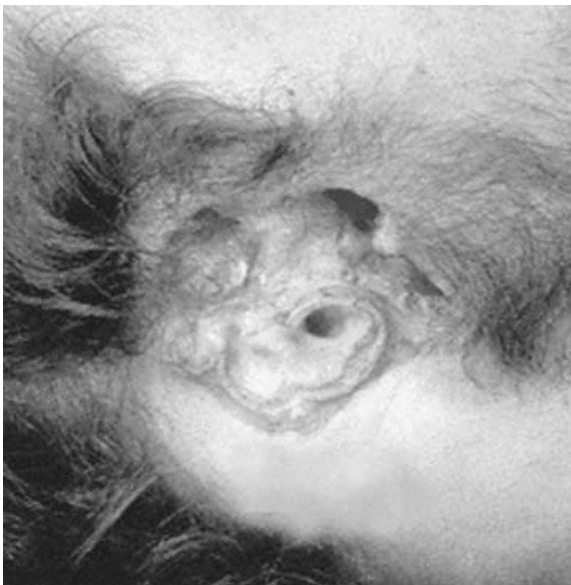

Figure 1.88 Notice the lack of blood around the area where the ear is missing. A rat had chewed off this man's ear after he died in a car.

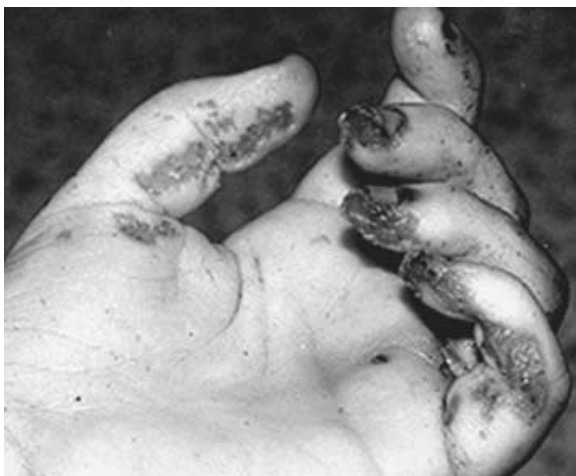

Figure 1.89 Most postmortem injuries are usually red-brown to brown with a lack of blood in or around the wounds. However, they may be red if the area is in a dependent position.

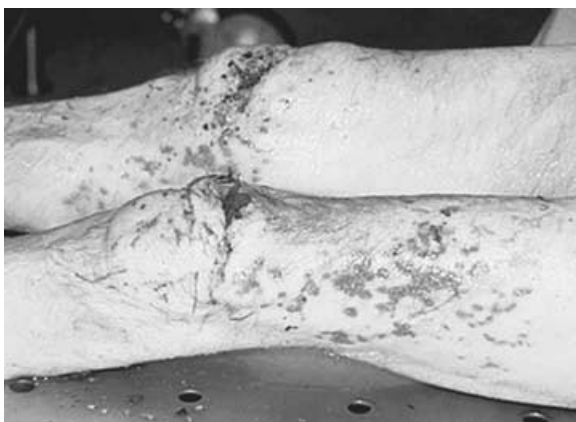

Figure 1.90 These injuries were caused by insects. The man was clothed and wrapped in a blanket. They are somewhat more red than usual. See photos 1.42 and 1.43.

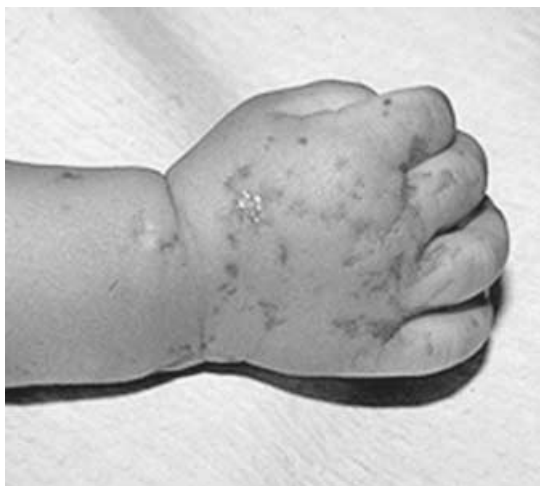

Figure 1.91 Another example of anthropophagia by ants or roaches. This baby was thought to have been abused. An emergency room physician saw these marks and became suspicious. The child died of SIDS.

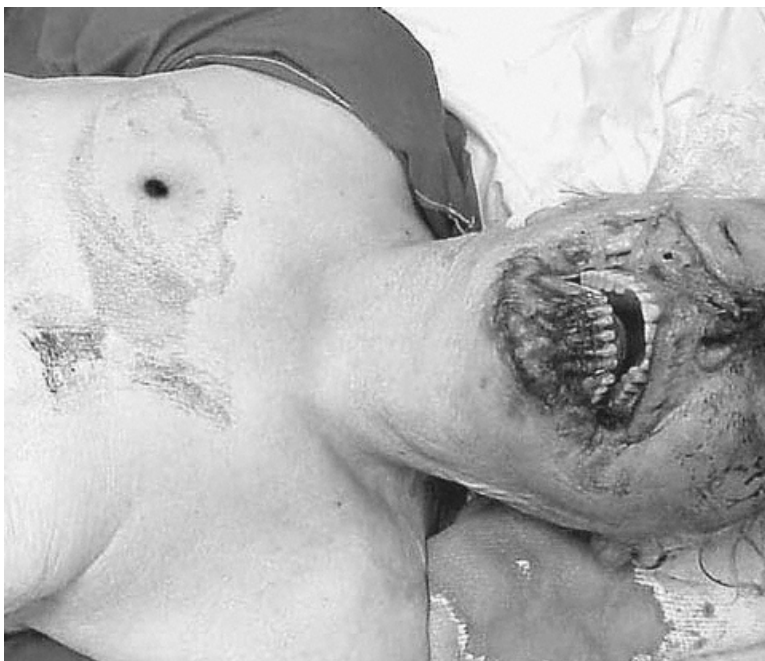

Figure 1.92 This woman was shot in the chest. Her body lay on the floor for two days prior to discovery. See next photo.

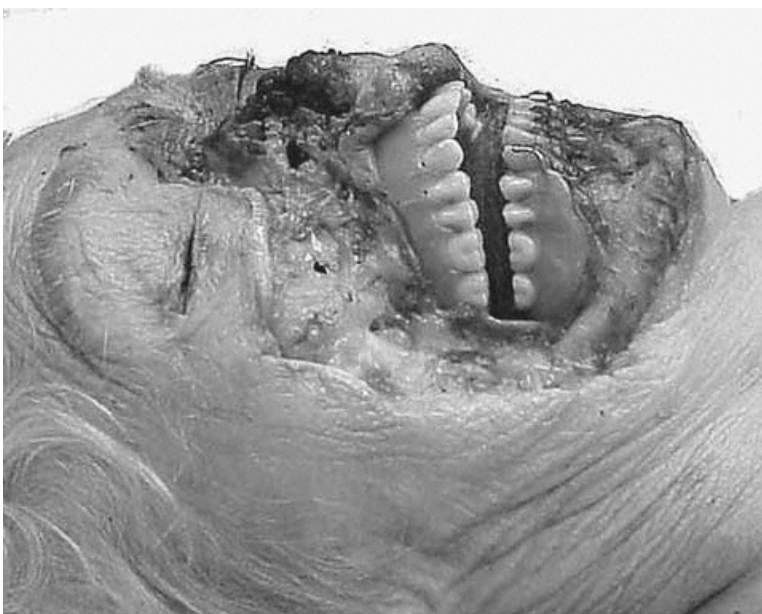


Figure 1.93 Her face was chewed by her cat. See next photo.

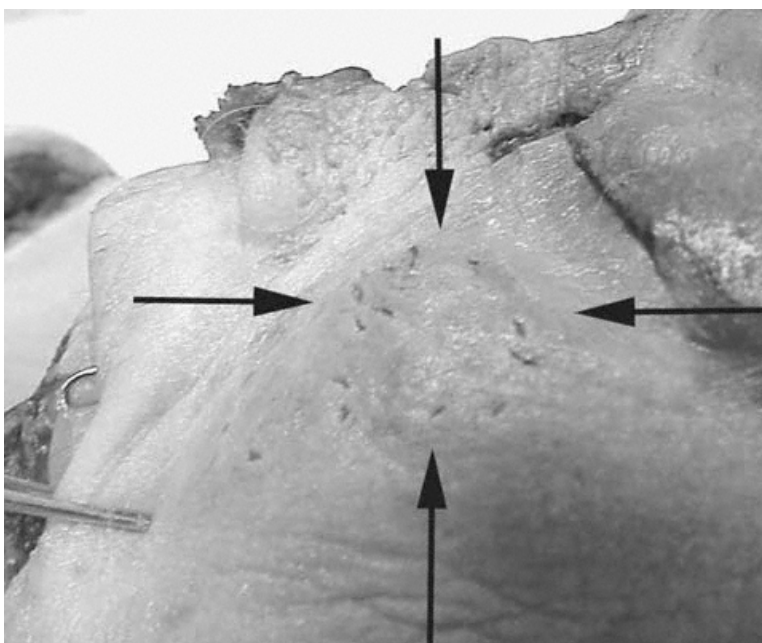


Figure 1.94 Teeth marks from the cat were apparent on her cheek.

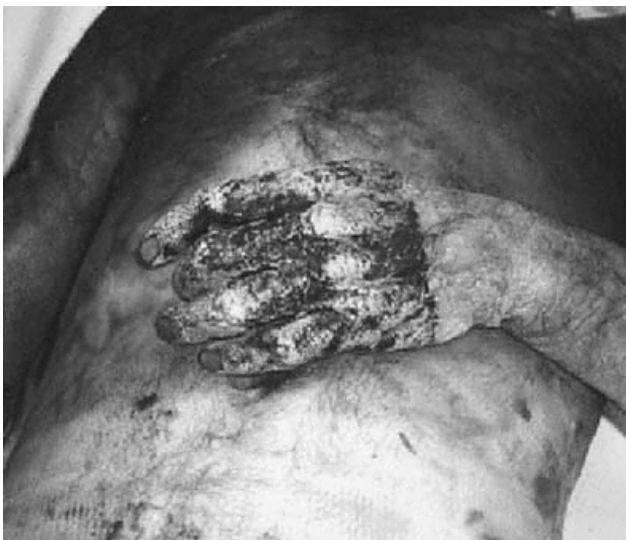

Figure 1.95 Notice the difference between the skin of the hand and the rest of the body in this drowning victim. See next photo.

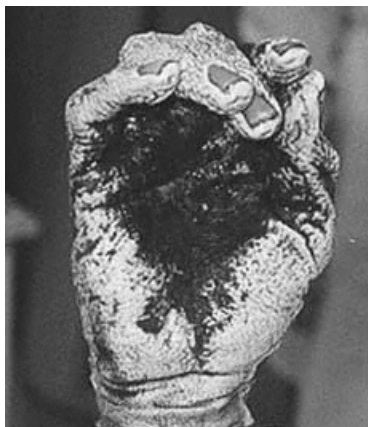

Figure 1.96a A close-up view of the hand shows the dramatic wrinkling of the skin. Had the person been in the water longer, the skin might have easily slipped off like a glove.



Figure 1.96b The skin and toenails will also slip off the feet in drowning, heat, and decomposition.

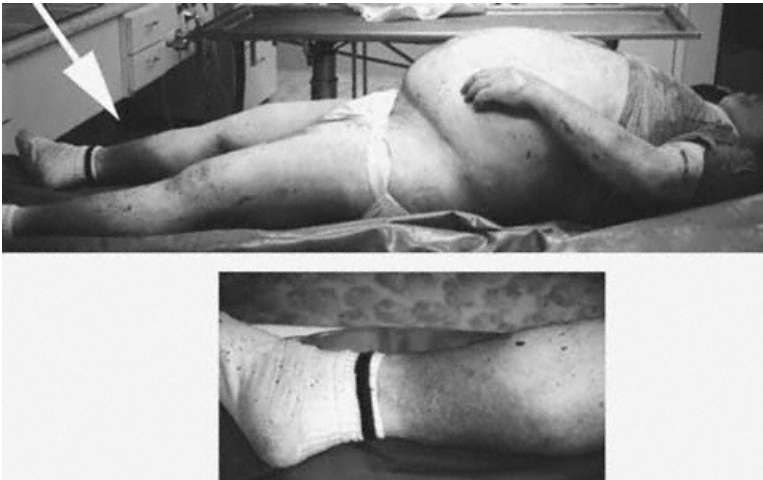

Figure 1.97 The discoloration of this man's legs is from heart failure and not decomposition or livor mortis.

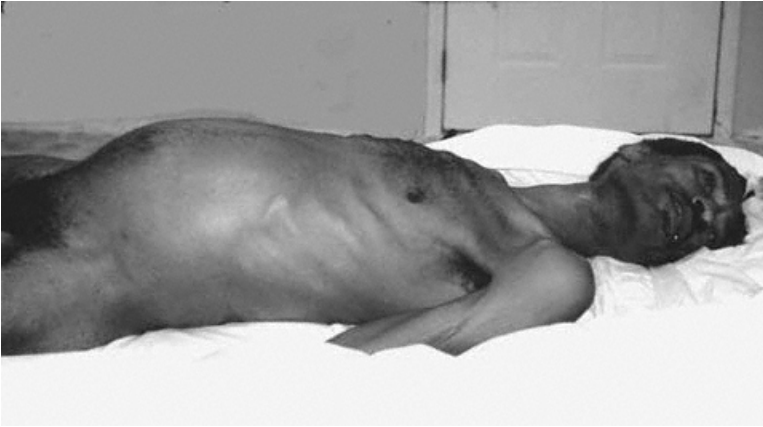

Figure 1.98 Swollen abdomen from fluid buildup due to cirrhosis of the liver and not decomposition.

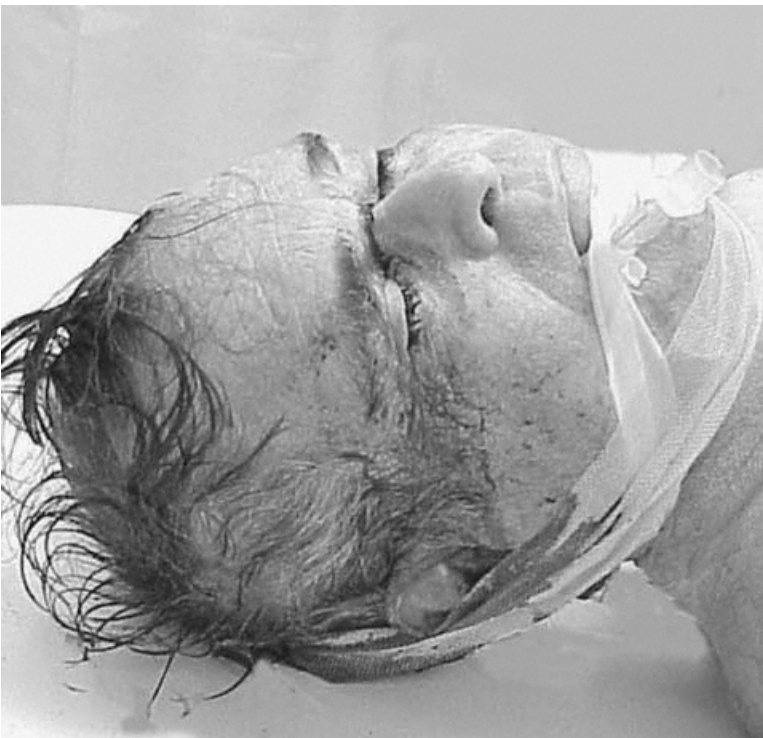

Figure 1.99 Blood from the eye after eye donation.

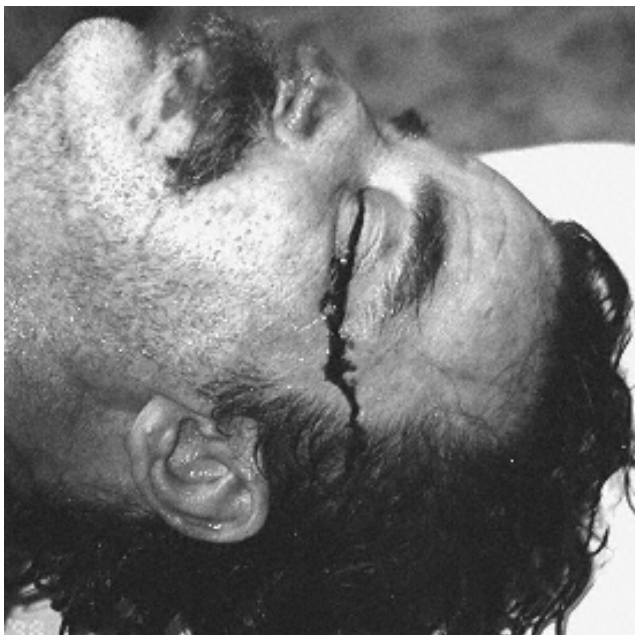

Figure 1.100 Another example of hemorrhage from eye donation.

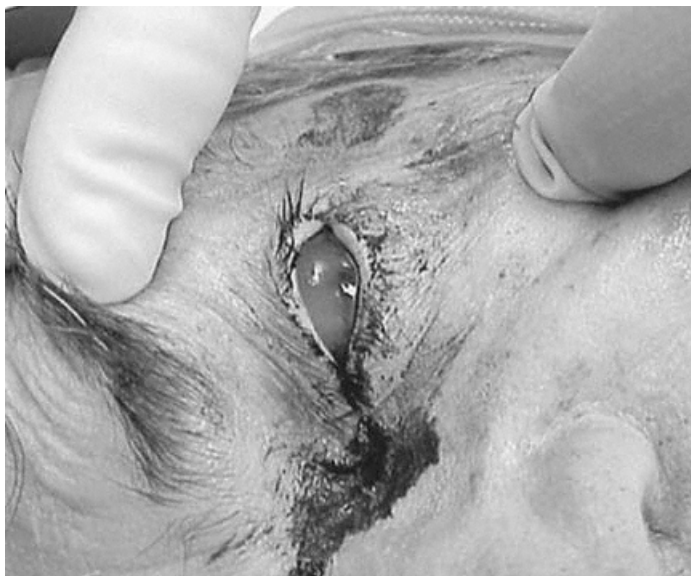

Figure 1.101 A Plastic eye replaces the original eye after donation.

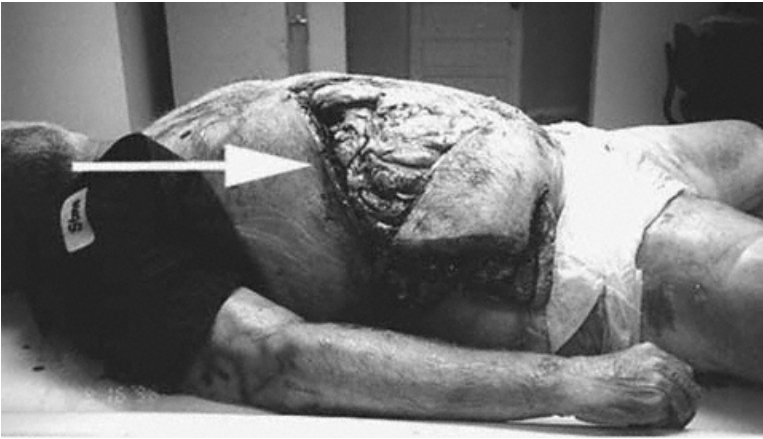

Figure 1.102 This man's body is decomposing after his abdomen was initially opened for liver and kidney specimen removal for toxicology.

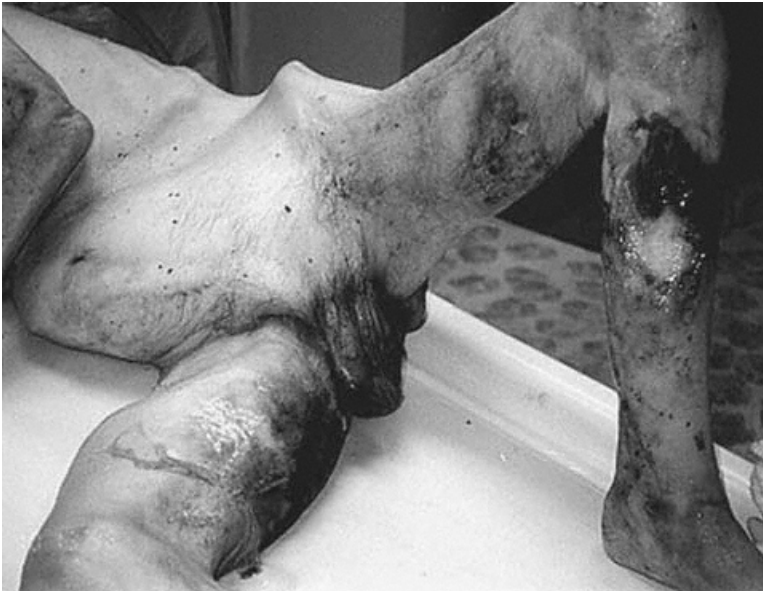

Figure 1.103 Decubitus ulcers (bed sores) in a case of elderly abuse. Not a postmortem injury.

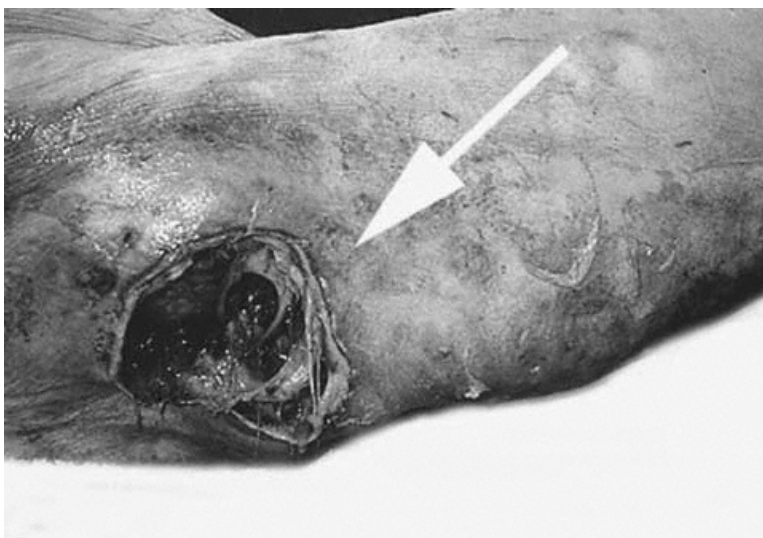


Figure 1.104 Decubitus ulcer of the hip.

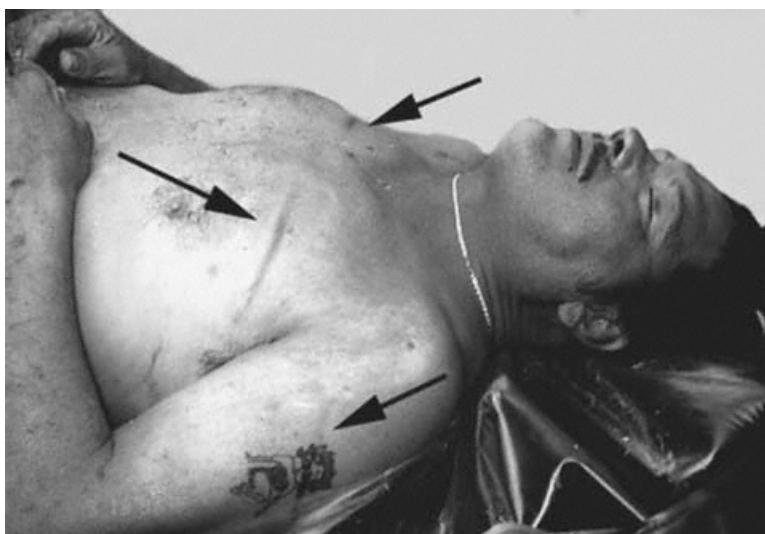


Figure 1.105 Marks from straps used to secure the decedent onto the stretcher. These are not antemortem injuries.

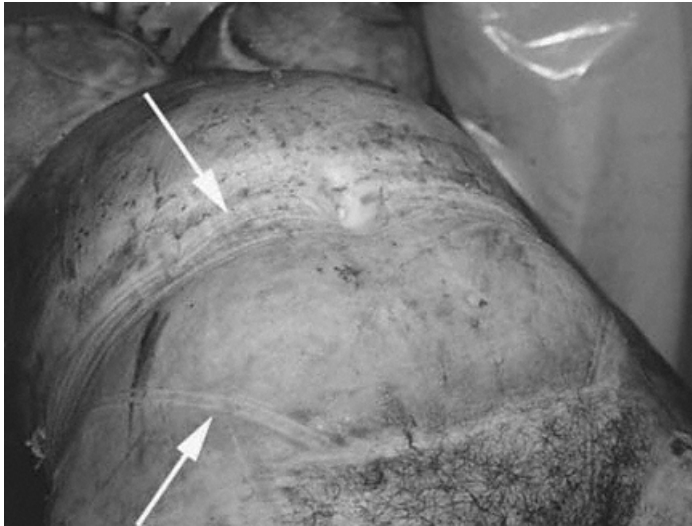


Figure 1.106 Panty line marks are quite apparent after decomposition occurs.

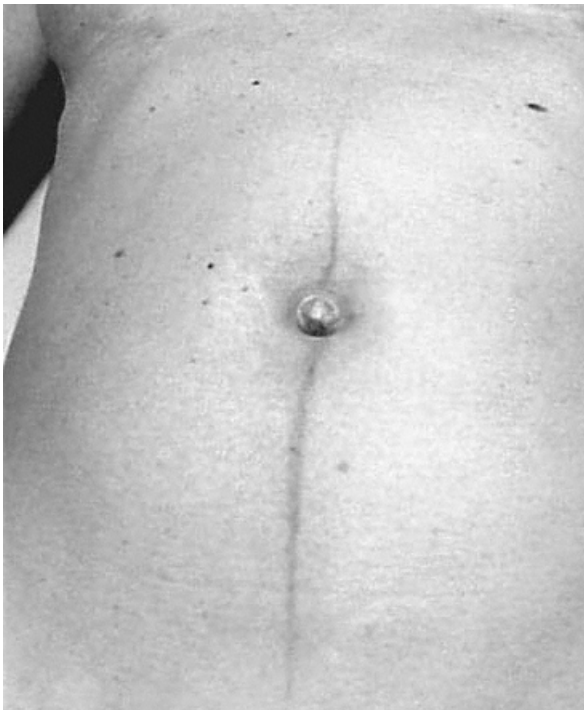

Figure 1.107 Normal discoloration of the skin on the abdomen (not from a scar or injury).

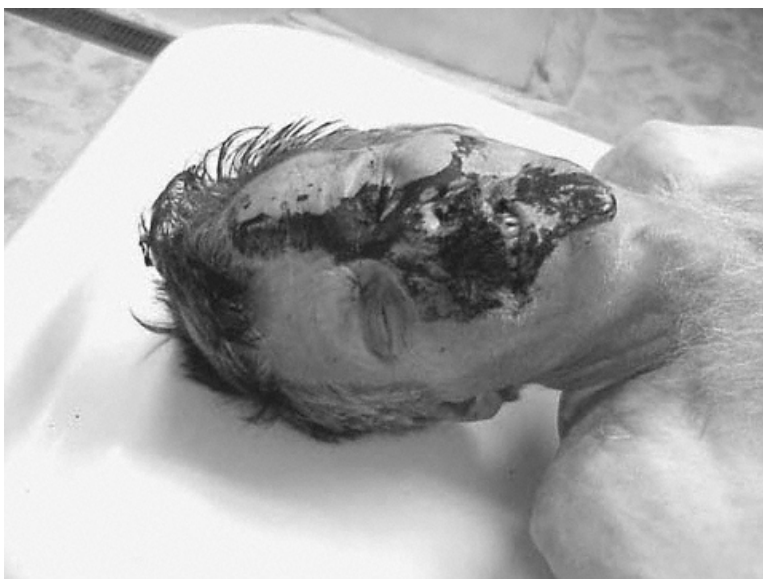

Figure 1.108a Vomitus on the face. Vomit and aspiration is rarely the sole cause of death. Many people vomit when they are dying.

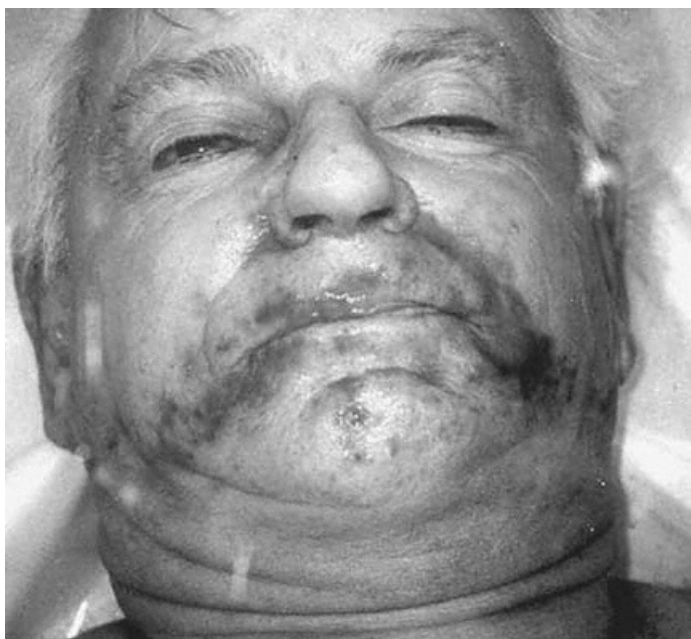

Figure 1.108b Superficial abrasions on the face from acid in vomitus or gastric contents. See next photo.

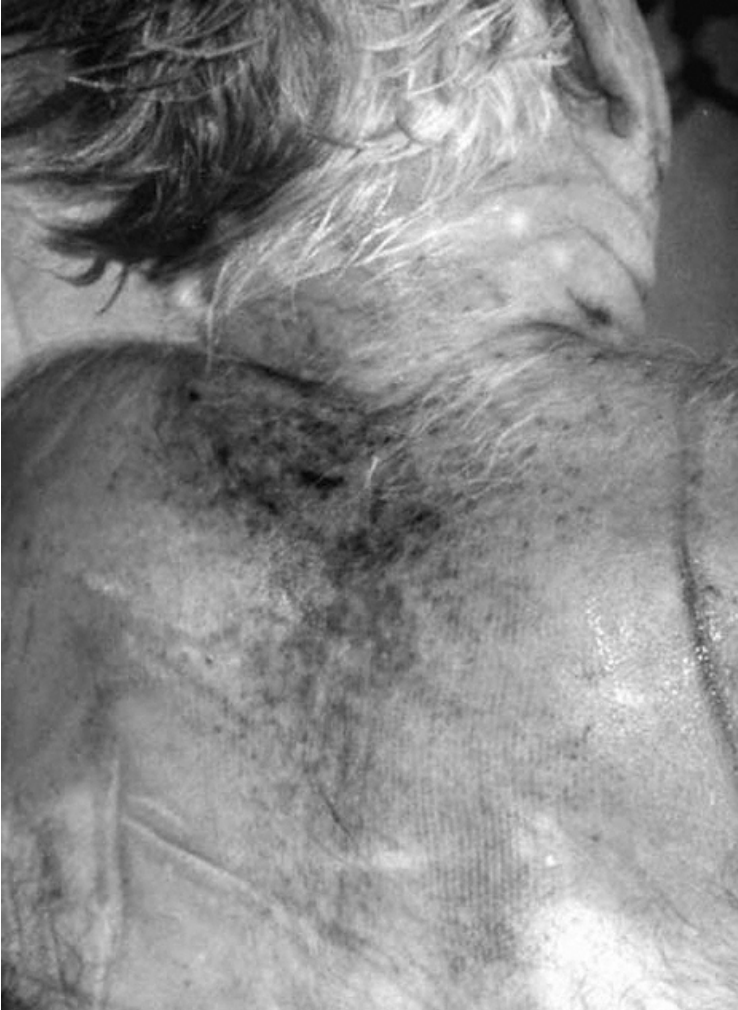

Figure 1.108c There were similar lesions on his back as well.

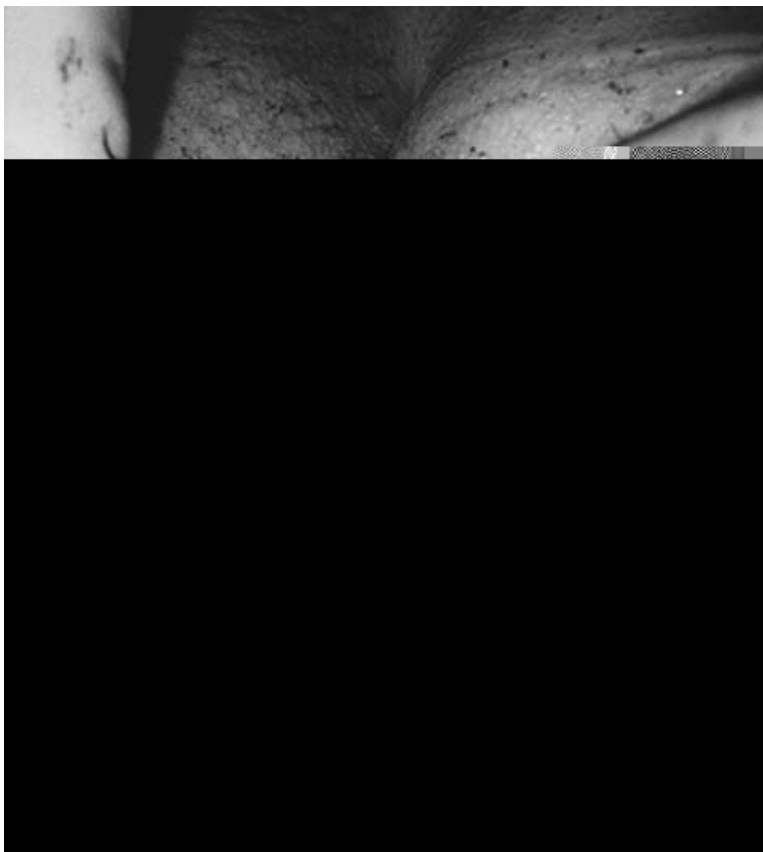

Figure 1.109 Postmortem dilatation of the rectum. There are no injuries. It is not a sign of sodomy.



Figure 1.110 This woman was bludgeoned to death and left on the side of the road. See next photo.

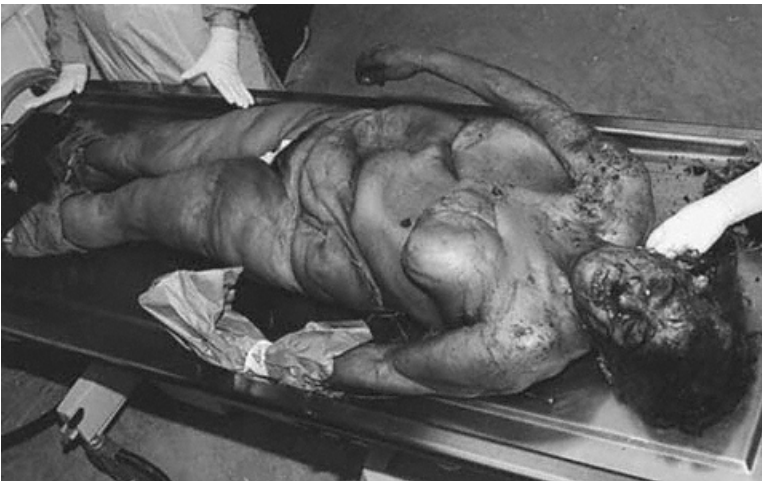

Figure 1.111 The cold caused her skin and soft tissues to have a doughy consistency.

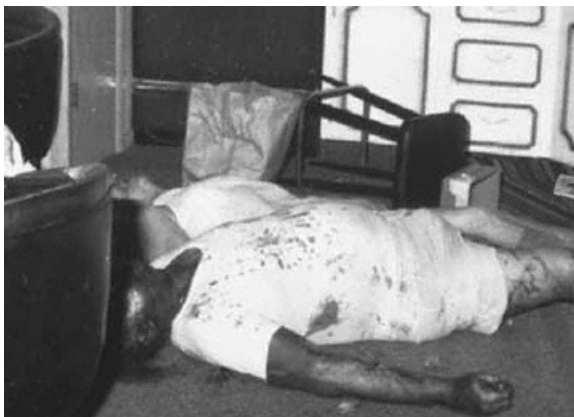

Figure 1.112 A couple with a handicapped son was visited every week by a visiting nurse that worked with the son. She came for her weekly visit and discovered the couple on the kitchen floor. See next photo.

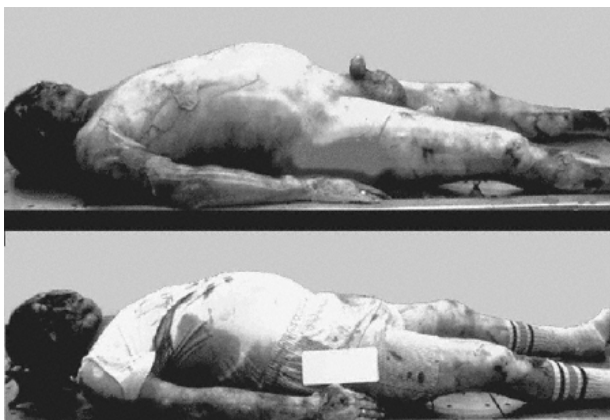

Figure 1.113 The man had been dead for 4–5 days. The degree of his body's decomposition was consistent with the mail and newspaper buildup outside the house. Autopsy revealed significant coronary artery disease as a cause of death. See next photo.

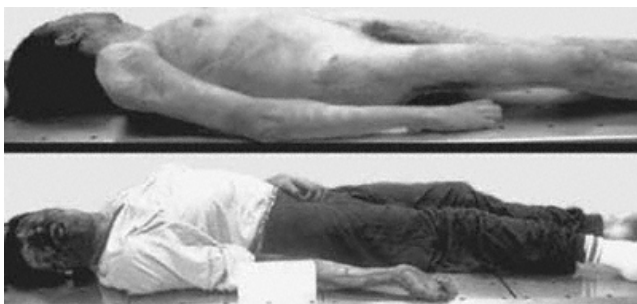


Figure 1.114 The son was not as decomposed as the father was and his lividity was cherry red. Autopsy revealed physical deformities (he was confined to a wheelchair) and a carbon monoxide level of 30%. There was no other cause for his death. See next photo.

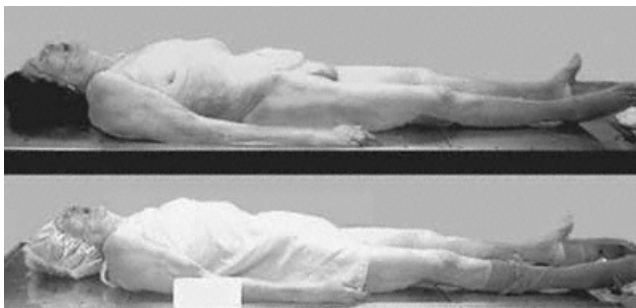


Figure 1.115 The mother's body was not decomposed. Autopsy revealed cardiomegaly, pericarditis, and aortic stenosis. Toxicology was negative for all drugs, including the digoxin she was supposed to be taking. See next photo.

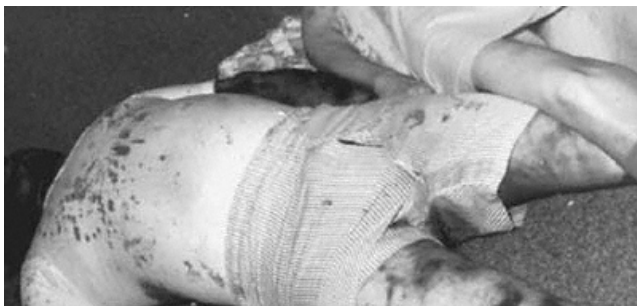

Figure 1.116 A closer look at the original scene shows the wife with her leg over her husband's leg. The only thing out of place at the scene was an overturned stool next to the bodies. A car in the garage was empty of gas and the key was in the "on" position. See next photo.

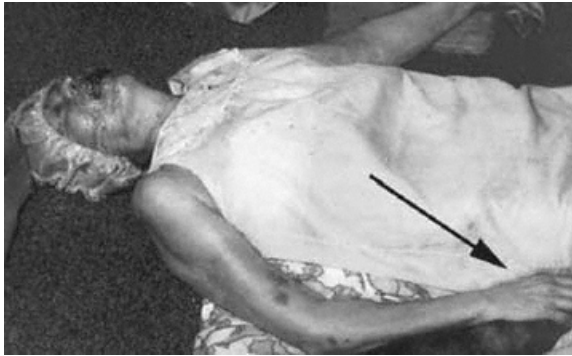

Figure 1.117 In summary: The father died first of heart disease. The wife killed the son by carbon monoxide in the garage and then killed herself. At the end, she lay next to her husband, grabbed his hand (arrow), and waited for death. Their physician confirmed the fact that the husband and wife had a suicide pact; if one of them died, the other would kill the son and then commit suicide.

A very important question to answer in any death investigation is the identification of the decedent. Identification of the decedent allows his or her family and acquaintances to grieve and settle the decedent's affairs. In addition, investigation of the death is greatly facilitated when the identity of the decedent is known. In non-forensic deaths, identifying the decedent is rarely a concern because most people die at home or in a health care facility. Identification is more often problematic in forensic cases because death may occur away from home and the next of kin may not be available to view the body; death occurs away from home and no identification is present on the body; a person lives and dies alone; false identification may be present on the body; or injury and/or postmortem changes preclude visual identification of the decedent.

Identification can be carried out in a variety of ways. It is convenient to categorize the means of identification as positive or presumptive. Positive identification entails scientifically establishing identity through the presence of known unique characteristics. Positive methods of identification include fingerprints, footprints, dental characteristics, radiographic comparisons and the presence of certain permanently implanted unique medical devices. The current state of DNA technology is generally considered a method of positive identification recognizing that an identical twin would be expected to carry the same DNA pattern. Presumptive methods of identification include those relying on non-unique or inconstant factors such as clothing, physical characteristics, circumstantial evidence, exclusion and visual identification. All methods of identification require that a known characteristic of an individual (even if it is a family member's DNA) be compared with the same characteristic of the unknown decedent.

The identity of most decedents in the U.S. is established by direct visualization. Under the appropriate conditions, this type of identification is quite acceptable and does not need to be supplemented with some other form of positive identification.

Positive Identification

Visual Identification

As noted above, the identification of most decedents is satisfactorily established by means of viewing the facial characteristics. Family members or close acquaintances are notified of a death and may go to the hospital, morgue or funeral home to confirm the identity of a decedent. In these cases, other information has led authorities to think that the decedent is a certain specified individual. Visual identification of a dead person may be quite unpleasant for the family. Some jurisdictions require the next of kin to visually identify the decedent in person while other jurisdictions may allow identification by viewing a photograph of the decedent. Some jurisdictions may rely solely upon rapid scientific identification if it is available and suggest that relatives avoid looking at the body until it is ready for viewing at the funeral home. In many cases, even if identification has been established scientifically, family members still want to see the body to “make sure” it is their loved one.

Even though this method of identification is the most common, in some ways is the easiest and is rarely incorrect, it is not without problems. Family members may mistakenly identify a person as their loved one because the authorities have told them that is who the dead person is supposed to be. Family members have been seen to make visual identification while their eyes were closed. Similarly, they may mistakenly not identify their loved one because emotionally they are in denial about the possibility of his or her death. Blood, disfiguring injuries and decomposition each make visual identification hazardous. Changes that exacerbate emotional responses or that obscure identifying features may make visual identification unreliable. Rarely, misidentification is intentional (fraud). If the examiner is at all unsure about the reliability of a visual identification, some other method of identification should be used.

Many methods used to identify a decedent may also serve as methods to exclude identity. Identity is easily excluded by radiography, dental examination, DNA analysis and fingerprints.

Fingerprints

A common means of positive identification is fingerprint comparison. To date, no two sets of fingerprints have ever been shown to be identical, even those of identical twins. Approximately 200 million people have their fingerprints on file with law enforcement and/or other agencies. Since the science of fingerprinting has advanced significantly over the last 50 years, mistakes in fingerprint identification rarely occur. Advances in technology

have helped agencies store fingerprint data and electronically search their files for possible matching prints, thereby shortening the time it takes to make matches of the unidentified body to a known individual. Even in this age of computerized searching, the final match is still made manually by a qualified fingerprint analyst.

Even if an individual did not have fingerprints on file with some agency, it may still be possible to do a fingerprint comparison. In these cases, fingerprints may be obtained from objects or surfaces that the person who is thought to be the decedent has touched, such as a mirror at home, bathroom articles, office articles, etc. Obviously, it is important in this situation to make sure that the exemplar prints do indeed belong to the person who was supposed to have left them.

The basic fingerprint ridge pattern resides in the dermis. As previously discussed, even after skin slippage, the dermal ridge pattern is still available for evaluation. The fingerprint pattern may also be recovered from the layers of skin that have slipped from the body. Recovering fingerprints from decomposed tissue may be difficult but experienced fingerprint experts using a variety of techniques have reasonable success in printing decomposed bodies.

In some cases, footprints may be used to establish identity. Footprints recorded at birth may be used for comparison purposes, especially for children. Unfortunately, a large number of the footprints secured at the time of birth are technically inadequate for comparison purposes. Additionally, many pilots have their footprints recorded since the foot is generally well-protected and may be relatively intact following a crash that extensively disrupts other portions of the body.

Dental

Most adults and many children have been to the dentist. In fact, more people have visited the dentist than have ever been fingerprinted. The unique characteristics of teeth (including reparative or cosmetic procedures) and jaw bones, coupled with their durability, make dental comparison an ideal method of identification. Antemortem dental radiographs can be compared with postmortem radiographs. A forensic pathologist sometimes will make the comparison in straightforward cases but rely on an odontologist in more complex cases and, often, cases involving homicides. In many jurisdictions, dentists perform all dental comparisons. As a practical matter, even in cases involving simple comparisons, next of kin and juries tend to feel more comfortable with the reliability of a dental identification if it has been made by a dentist. In some cases, a particular dentist may recognize his or her handiwork by examining a prosthesis from an unidentified decedent and thus provide a means of establishing identification.

Dental comparison is most often made using antemortem and postmortem radiographs. In some cases, antemortem radiographs may not be available. In some of these cases, dental comparison still may be possible by comparing the teeth seen in a photograph of the smiling individual with the teeth of the decedent.

Edentulous persons may also be identified through dental comparison methods. Radiographs including the bone structure of the jaws may offer sufficient unique detail to establish identity. Dentures sometimes are inscribed with the owner's name, social security number or other identifying information. Although it is tempting to rely on this type of information to establish identification, it must be kept in mind that dentures are not permanently implanted and may be used by someone else. We have seen over the years a couple of individuals who were wearing some other person's dentures when they died. Identifying information inscribed on dentures is best used as a bridge (pun intended) to other more positive means of identification.

Some children have not been to a dentist. If their remains are discovered, a positive dental comparison may not be possible; however, the pattern of tooth eruption might give an indication as to the age of the child.

The dentist can also check for wear patterns that might lead to indications of lifestyle habits (e.g., pipe smoking) and age. These findings may be useful in corroborating other information or narrowing the search for additional information about the decedent.

Radiographs (X-rays)

Many individuals have undergone at least one X-ray examination during their lifetime. These radiographs can be compared to postmortem studies either by forensic pathologists or radiologists. In general, it is preferable for anything other than straightforward radiographic identifications to be confirmed by a radiologist. Skull and pelvic radiographs tend to be the best for comparison because they have more points of bony variation, making them easier to match than the more commonly taken chest radiograph. For an adult, the skull may be the most useful radiograph since the pattern of the sinuses in the front of the skull is specific for each individual. Like fingerprints, no two sinus patterns in this region are exactly alike. In addition, radiographs depicting unique injuries or anomalies are also ideal for identification purposes.

The discovery of antemortem X-rays does not ensure a positive identification can be made even if the radiographs are of sufficient technical quality for identification purposes. There may not be enough points of comparison to consider the radiographic findings unique. A presumptive identification

may be made if the radiographs are consistent with those of the decedent and there is no other evidence to suggest the decedent is someone else.

DNA “Fingerprinting”

DNA (deoxyribonucleic acid) is the building block of human genetic material and is found in all cells of the body which have nuclei. Differences in the makeup of DNA of various persons make it possible to distinguish the DNA of one person from that of another. The results of DNA analysis has been called the DNA “fingerprint,” implying that the genetic composition is similar to our fingerprint in that it is unique to an individual. This is not quite true — identical DNA patterns are found in identical twins. However, excluding the existence of an identical twin, the DNA of an individual is unique. DNA testing is commonly performed in all states and its validity has been accepted by the scientific and legal communities.

Some medical examiners routinely save blood in all cases for DNA testing if it becomes necessary at some point in the future. For identification purposes, postmortem blood or tissue DNA analytic results can be compared to the results of testing performed on a known antemortem specimen. In some cases, an antemortem sample may not be available. In these cases, DNA samples can be obtained from family members and the analysis of these samples may demonstrate the decedent is from this particular family.

Blood collected during autopsy for DNA testing is also commonly used for other purposes such as the determination of paternity. The postmortem blood DNA pattern can be used to identify or exclude a parent-child relationship between two individuals. Some states are routinely collecting blood for DNA testing in an attempt to complete investigations in unsolved murders and sexual assaults.

DNA has been used to identify victims in cases where the body is missing. In Missouri, a man was convicted of shooting his wife in the head with a shotgun while she was seated in her car. The body was never found, but the car contained an abundant amount of dried blood, shotgun pellets and facial bone fragments. The blood in the car was proven to be the wife’s blood. Similarly, DNA was used to identify the source of fragments of brain tissue recovered from a car wash drain even though the remainder of the body was missing.

A form of DNA is found in cellular organelles called mitochondria. This form of DNA is unique in that it is inherited solely from the mother. Its usefulness for identification lies in the fact that it may be recovered from hair. Thus, hair from hairbrushes or electric razor debris may provide a source of DNA for comparison purposes. Mitochondrial DNA analysis is a specialized form of DNA testing and is performed in a limited number of laboratories.

Presumptive Identification

Physical Features

Tattoos, scars, birthmarks, the absence of organs from surgical procedures and other physical anomalies are helpful in making identifications. The presence or absence of any of these characteristics may be helpful in eliminating possible matches, as well as in making an identification. The strength of an identification made on individual or combinations of physical features will depend on the relative uniqueness of the feature(s).

A feature that may be very useful in making an identification is the presence of a permanently implanted medical device such as an artificial joint or a pacemaker. In the U.S., if these devices are removed, they are not allowed to be implanted into another person. Each of these devices bears a unique serial number. The manufacturer of the device can be contacted and the serial number can be used to identify the individual into whom the device was implanted, as well as when and where it was implanted.

Clothing and other Personal Property

The style, size and manufacturer of clothing and jewelry are commonly used to make a presumptive identification or to presumptively exclude identity. Relatives, friends or witnesses may remember what the missing person was wearing when last seen. Unfortunately, clothing may decompose along with the rest of the body or be destroyed if a body is burned. Of course, a person may not be wearing his or her “regular” clothes when death occurred or may not be wearing the same clothing when “last” seen. Identification should not be based solely on clothing since someone else may have donned the missing person’s clothing or the missing person may be wearing the clothing of some other person.

Similarly, personal property such as a driver’s license or social security card may offer important leads as to the identity of the decedent. However, since these documents can be borrowed, found or stolen, their presence should not be sole determinants of identity.

Circumstances Surrounding Death

Occasionally, it may not be possible to make a positive or presumptive identification based on the characteristics of the remains. In some cases, however, the circumstances in which the remains are discovered may allow identification to be made. For example, a decomposed body is found sitting in a chair facing the television set, which is on. The house is locked and no evidence of foul play is evident. The body is that of an elderly man who is clothed in the same attire the owner of the house was seen

in 5 days previous to the body being discovered. The owner of the house is a sickly elderly man with no known relatives and who did not believe in going to doctors. A diligent search to locate the owner of the house alive was unsuccessful. There was no reason to believe the remains were those of someone other than the owner. Under these circumstances, a presumptive identification of the body as the owner may be made. Similarly, circumstantial evidence may allow an extensively burned partially consumed body recovered from a house fire to be identified as the house's resident. Obviously, identification based on circumstances involves some risk of error and great care must be used when relying on this type of identification method.

A variant of circumstantial identification is identification by exclusion. As an example, a military jet with a crew of five crashed and burned during takeoff, resulting in extensive burning of the bodies of the crew. The crew was known to consist of four men and one woman. The remains were not visually identifiable; however, autopsies revealed one of the remains as those of an adult female and the others as males. By exclusion, identification of the woman was made since she was the only female member of the known flight crew.

Skeletal Remains

Skeletal remains are usually examined by a physical anthropologist, preferably a forensic anthropologist. Forensic anthropologists are experts in estimating age, gender, race and stature. A variety of measurements and formulae are used to arrive at their conclusions. Techniques are also available to reconstruct the facial characteristics of the decedent if the skull is available.

Age estimates in children may be arrived at by radiographic and dental techniques looking at bone ossification centers and dental eruption patterns. A variety of findings may also help categorize the age of an adult skeleton. Microscopic evaluation of bone which involves counting the number of osteons is one method of age estimation.

Identification of skeletal remains is accomplished using the same methods as in the identification of non-skeletal remains. Obviously, visual identification of skeletal remains is not valid.

Anthropologists may address issues other than the general skeletal characteristics. They are able to examine the remains for signs of injury and may be able to identify the nature of injuries (blunt force, sharp force, firearm) as well as whether the injuries were sustained antemortem or postmortem. Evidence of postmortem animal activity such as clawing and gnawing are typically readily recognized by the anthropologist.

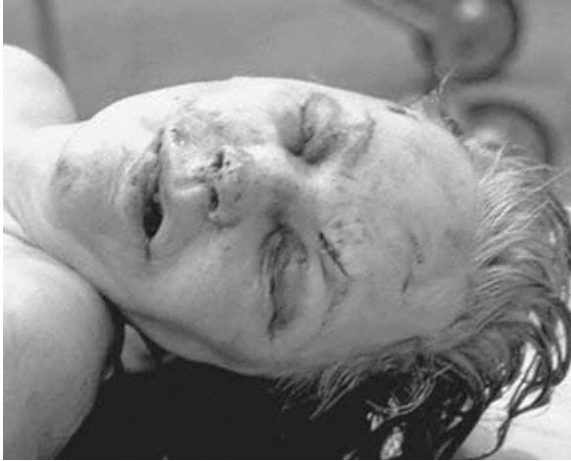

Figure 2.1 This woman's face was traumatized due to a motor vehicle accident. Care must be taken when asking the family for a visual identification (I.D.). Many family members or friends are hesitant to give a positive I.D. when the face has been injured. Visual identification may also be difficult in cases in which the decedent's body has undergone moderate decomposition.

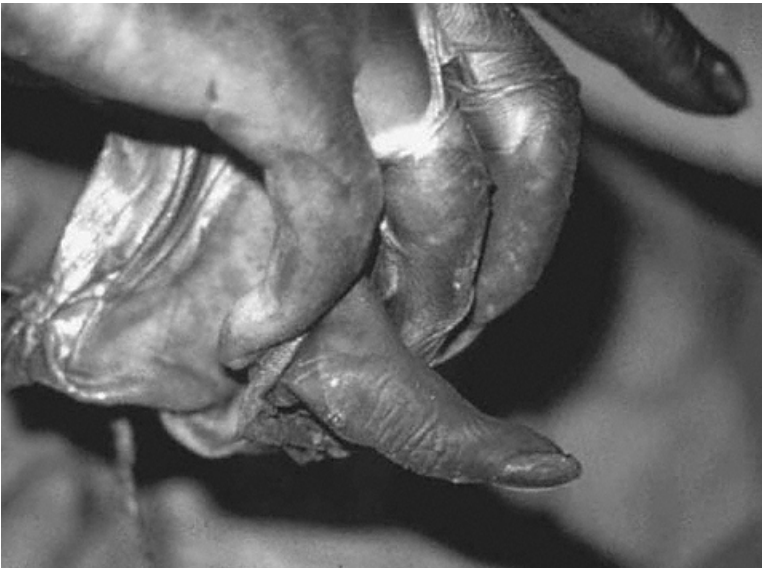

Figure 2.2 The skin and fingernail of this little finger have slipped off due to the heat. Only the skin is needed to make a fingerprint.

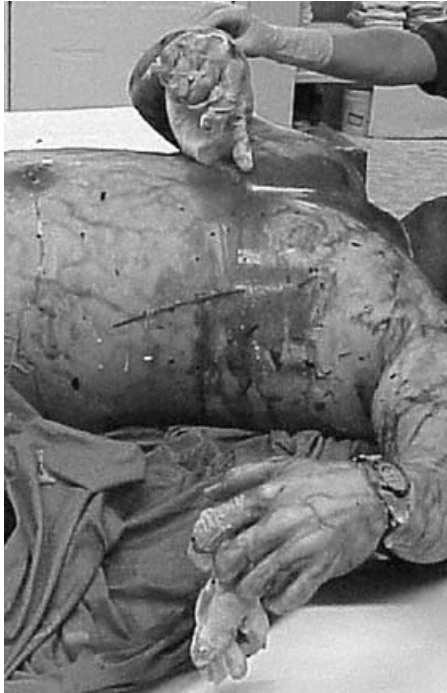

Figure 2.3 This decomposed man has marked skin slippage of the hands. See next photo.

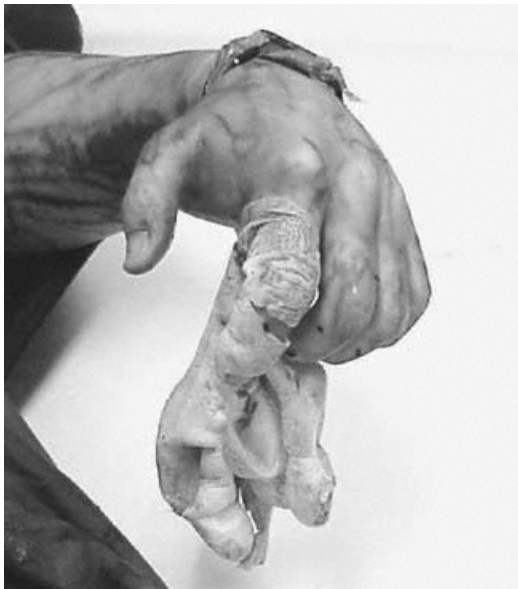

Figure 2.4 Close up of the left hand. See next photo.

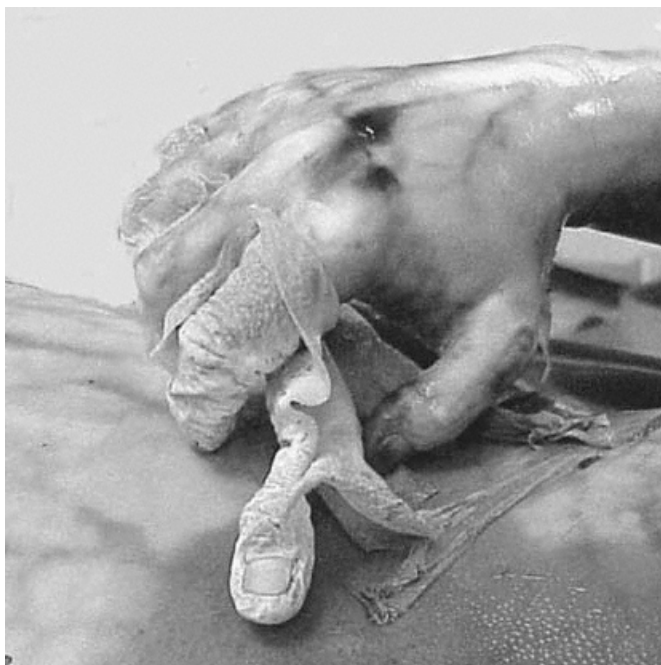

Figure 2.5 Close up of the right hand.

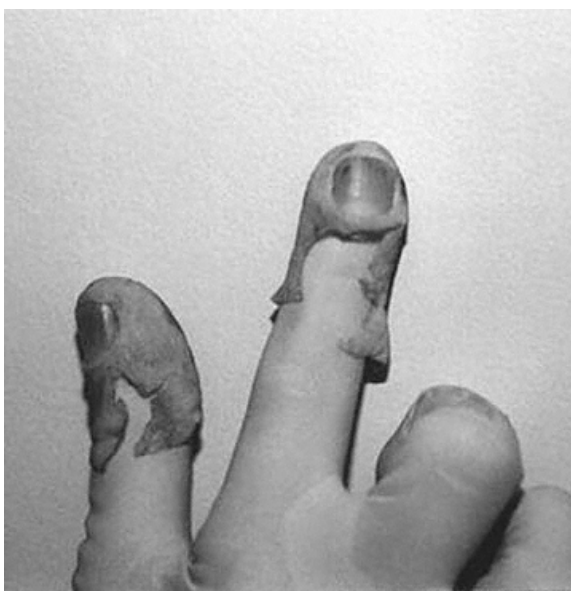

Figure 2.6 The skin on the ends of the fingers can be removed and placed on the examiner's hand for printing. See next photo.

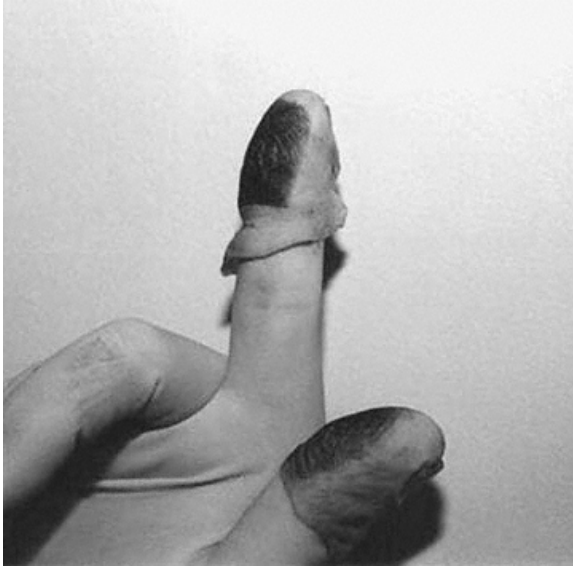

Figure 2.7 Printed skin.

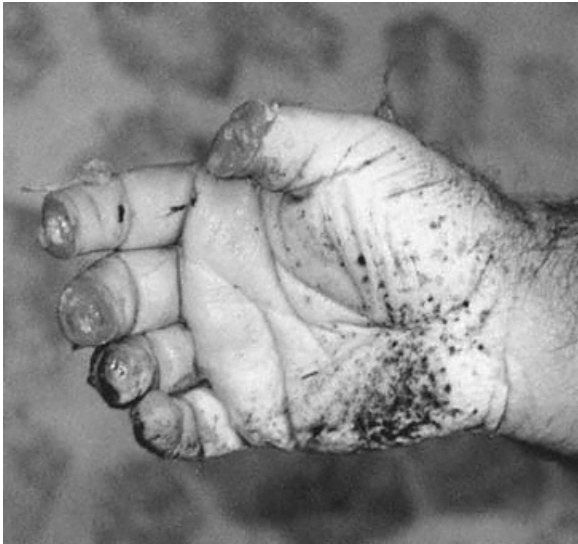

Figure 2.8 If necessary, the ends of the fingers or hands may be removed and sent to the lab for printing.

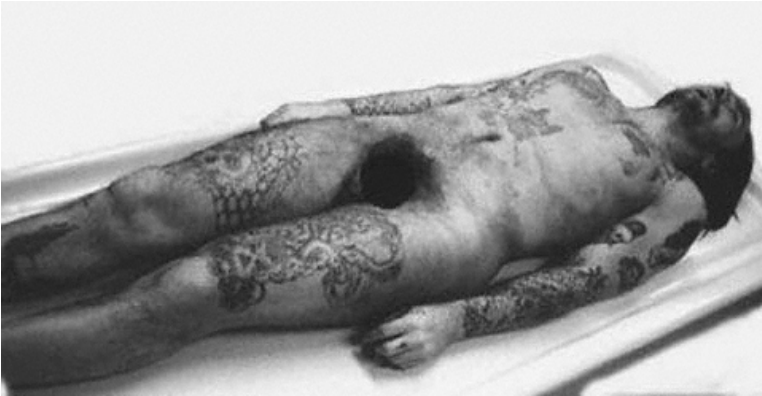

Figure 2.9 Tattoos may be good for both probable and positive I.D.s.

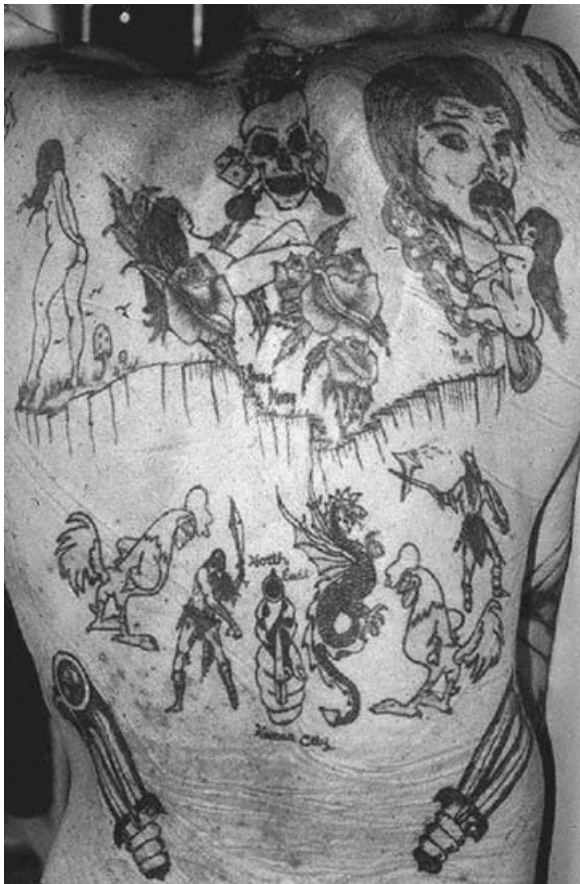

Figure 2.10 Occasionally tattoo artists are able to identify their work.



Figure 2.11 Some tattoos may be cute, but not very unique. However, they still may aid in eventual identification.

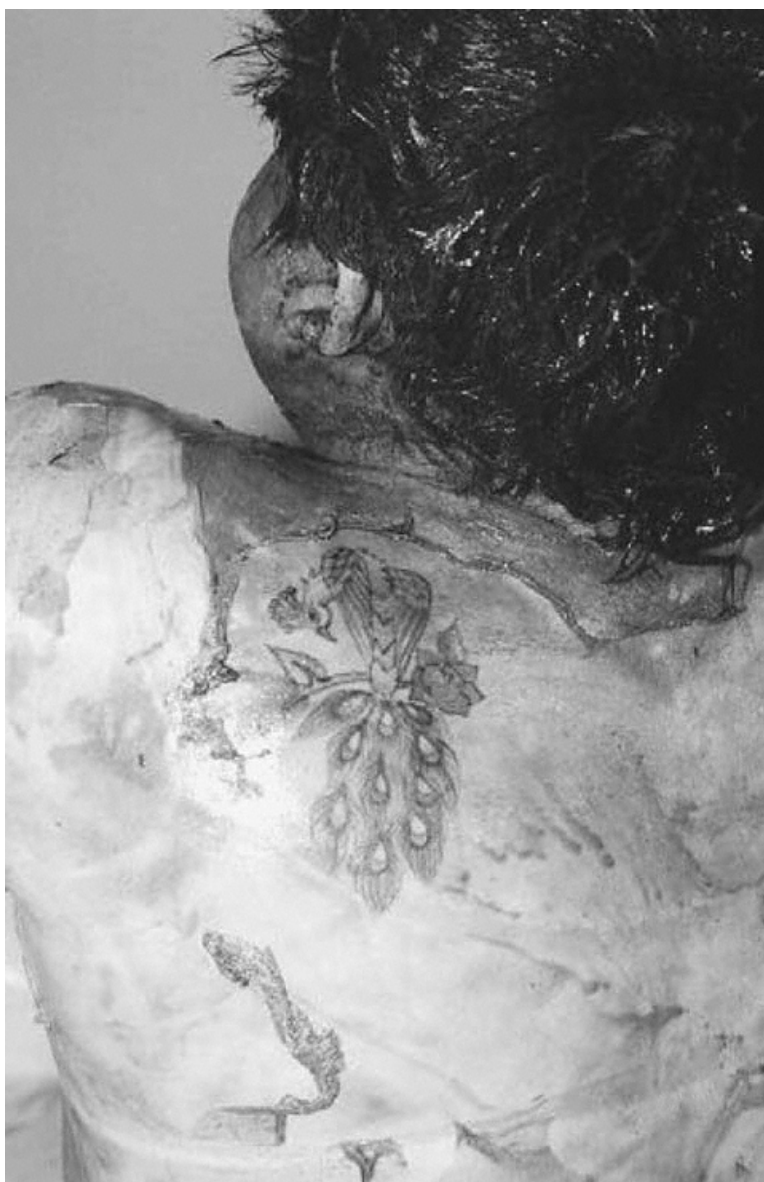

Figure 2.12 Tattoos can be readily observed on decomposed bodies with skin slippage.

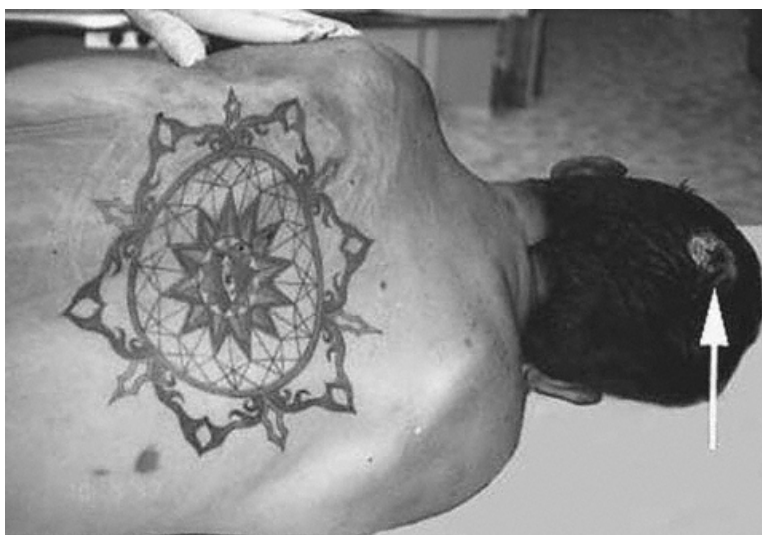

Figure 2.13 A unique tattoo on an individual with a gunshot wound to the head (arrow).

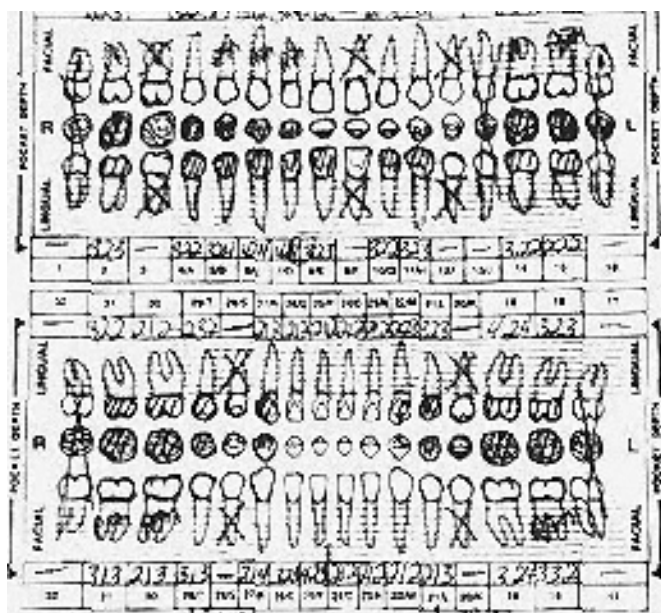


Figure 2.14 A typical dental chart used to make a positive identification. The teeth are numbered from the upper right molar (#1), across to the upper left wisdom tooth (#16) and then across the bottom from left (#17) to right (#32).

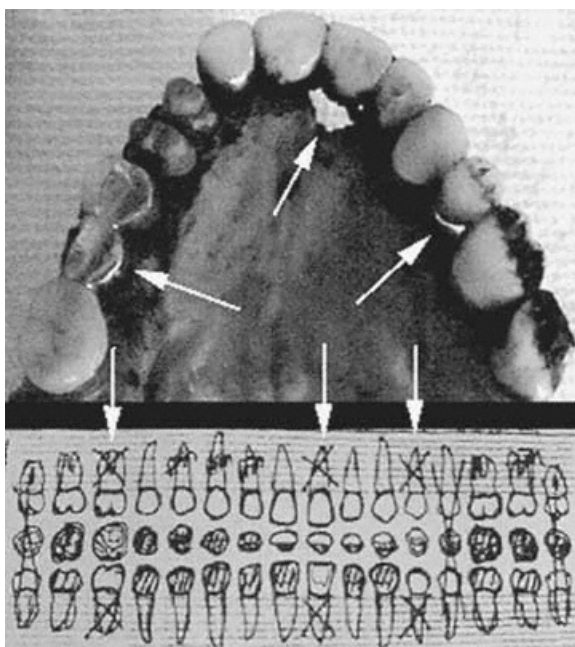


Figure 2.15 This is an example of numerous points of positive matches (arrows).



Figure 2.16 The teeth may withstand extensive thermal injury and decomposition. Even though this body is charred, the teeth remain a good source for identification. See next photo.

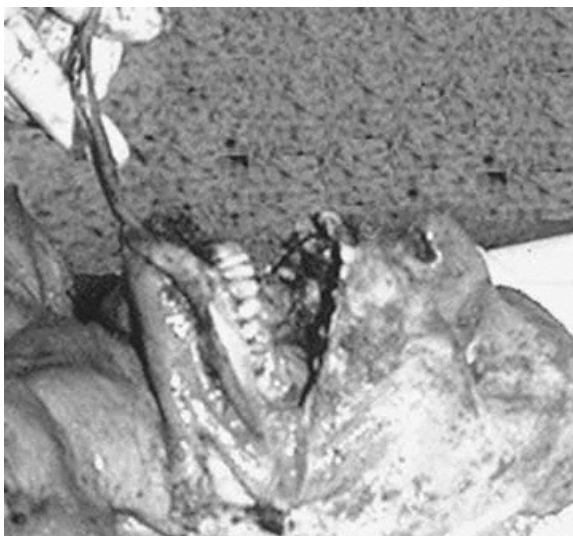

Figure 2.17 The jaw may need to be removed and retained for I.D. purposes. The skin and soft tissue around the jaw are cut and reflected prior to removing the bone. See next photo.



Figure 2.18 An oscillating saw is used to remove the maxilla and mandible.

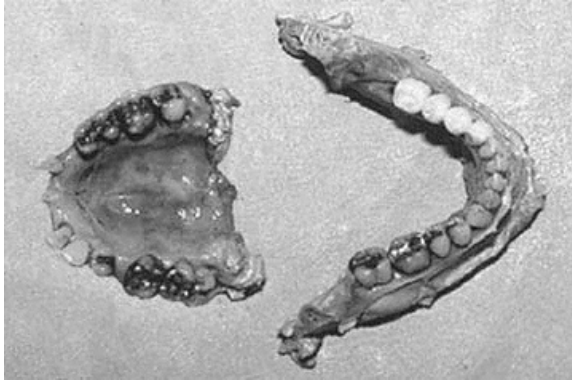


Figure 2.19 Once removed, the maxilla and mandible (right) can be easily examined and X-rayed.

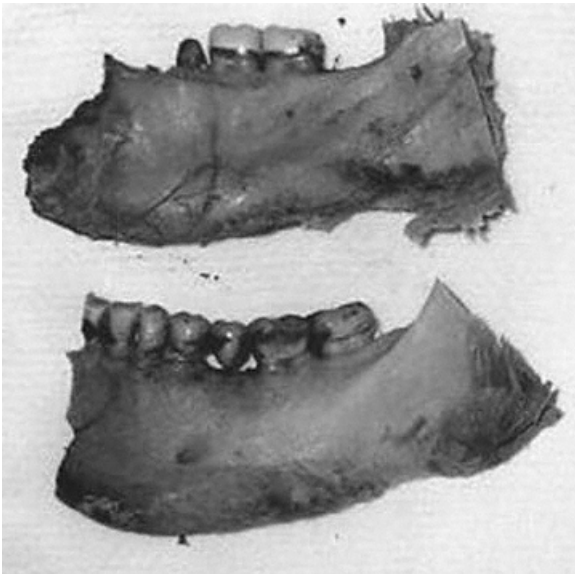


Figure 2.20 These two portions of a mandible have identifiable dental work that made I.D. easy.

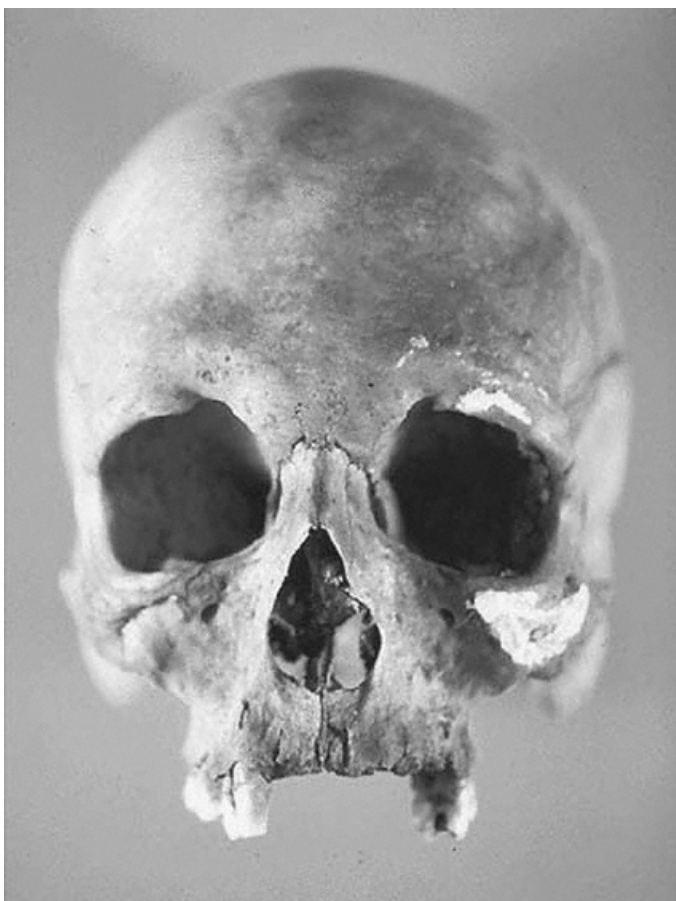


Figure 2.21 This skull was discovered with other parts of a skeleton. The police thought they knew the decedent's identity; however, a positive I.D. had to be made.

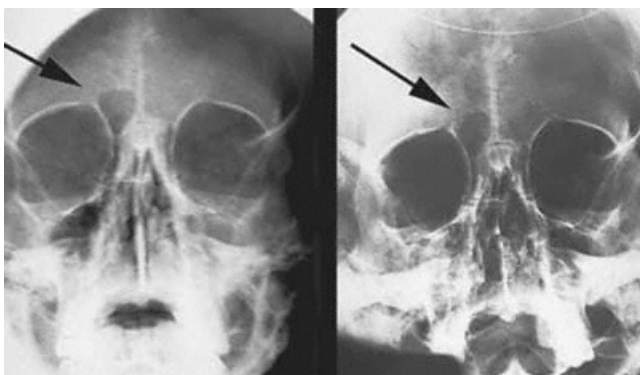

Figure 2.22 A skull X-ray from a previous traffic accident was available for comparison. The arrows point to the frontal sinuses on the antemortem (left) and postmortem films. The sinuses are the same.

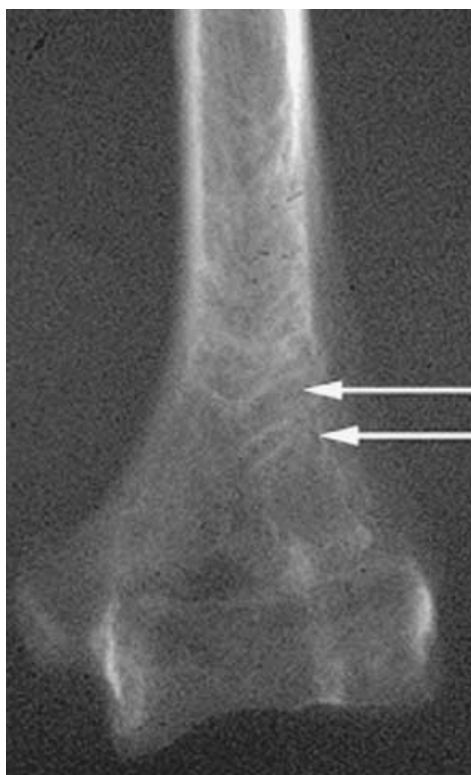


Figure 2.23 Individual growth lines in the bone (arrows) can be used for I.D.



Figure 2.24 This body was discovered in a field. It was thought to be that of an African-American man who was shot in the abdomen during a barroom brawl. In order to prosecute the assailant, a positive I.D. needed to be made. See next photo.

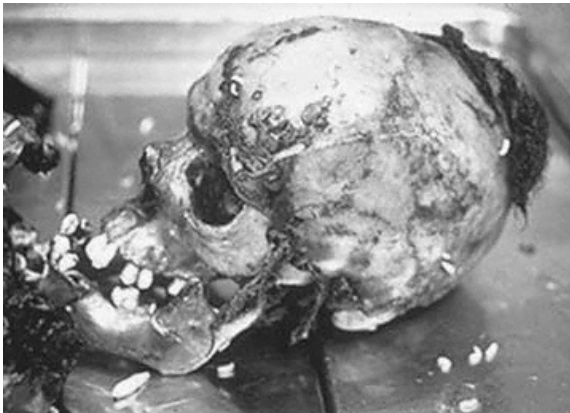

Figure 2.25 An examination of the skull revealed black curly hair and the jaw of a man. The teeth appeared as if no dentist had ever worked on them. The findings are consistent with those of an African-American man; however, positive proof must be made. See next photo.

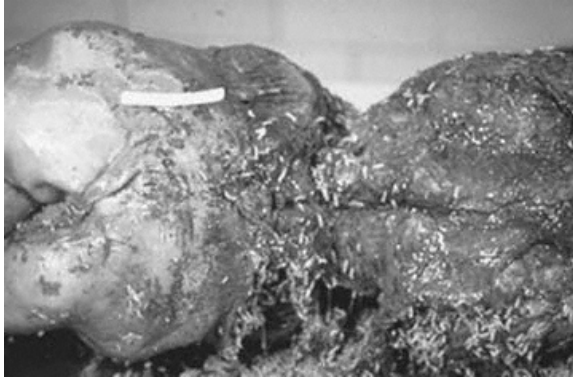

Figure 2.26 There was moderate decomposition to the torso with abundant maggots. Notice the difference in the degree of decompositional changes between the torso and the skull in the previous photo. See next photo.

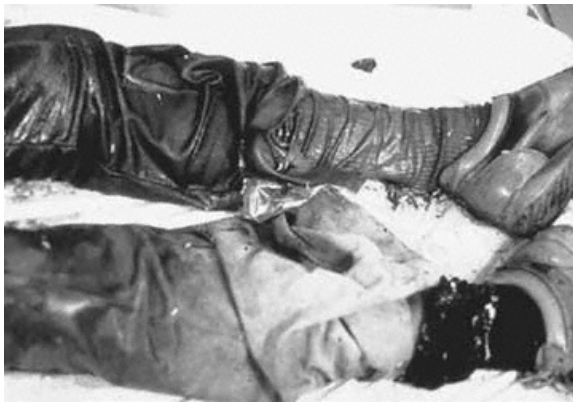

Figure 2.27 The clothing was consistent with those worn by the man when he was shot. This is still not enough for a positive I.D.. See next photo.

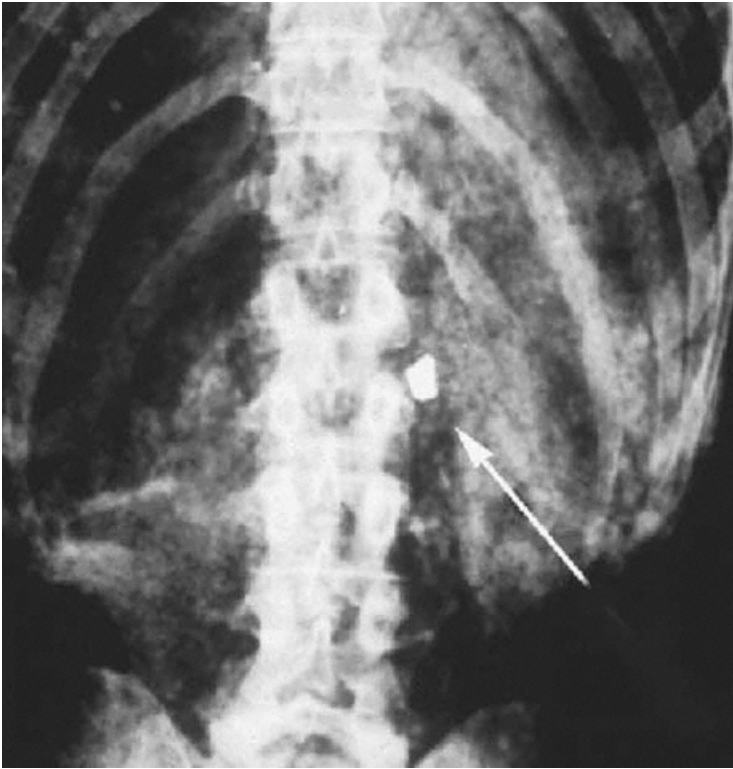


Figure 2.28 A postmortem X-ray revealed a bullet (arrow) next to the spine. There was no scar tissue around the bullet. This proved he had recently been shot. See next photo.

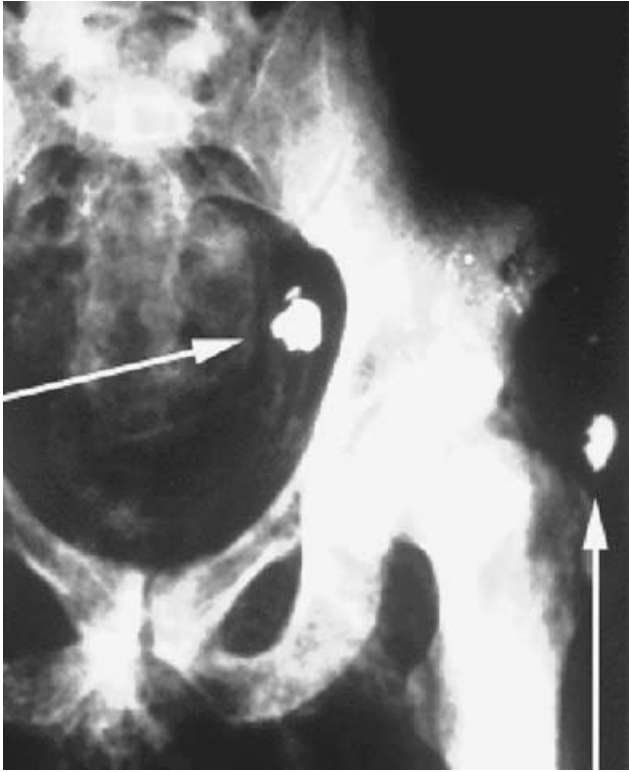


Figure 2.29 An X-ray of the pelvis revealed bullet fragments. These fragments were surrounded by scar tissue, indicating the man had been shot before. See next photo.

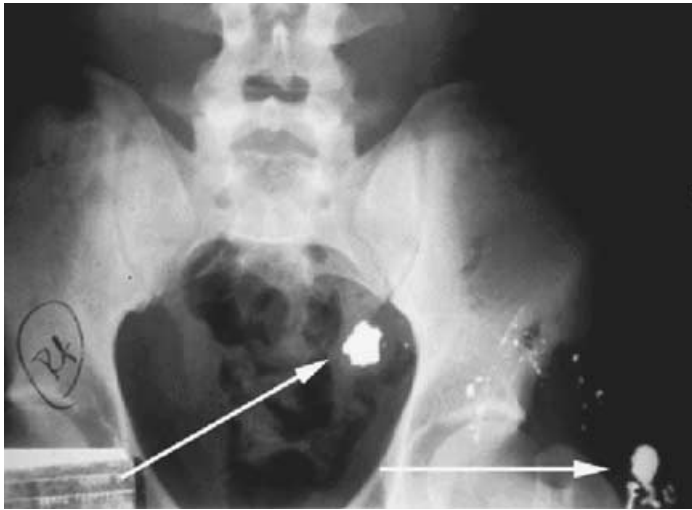

Figure 2.30 An eight-year-old X-ray from the probable victim revealed the same fragments as seen on the postmortem radiograph. See next photo.




Figure 2.31 A comparison of the two X-rays revealed not only a match with the bullet fragments, but also a match of the pelvic bones. Now there is positive I.D. and the assailant can be prosecuted.

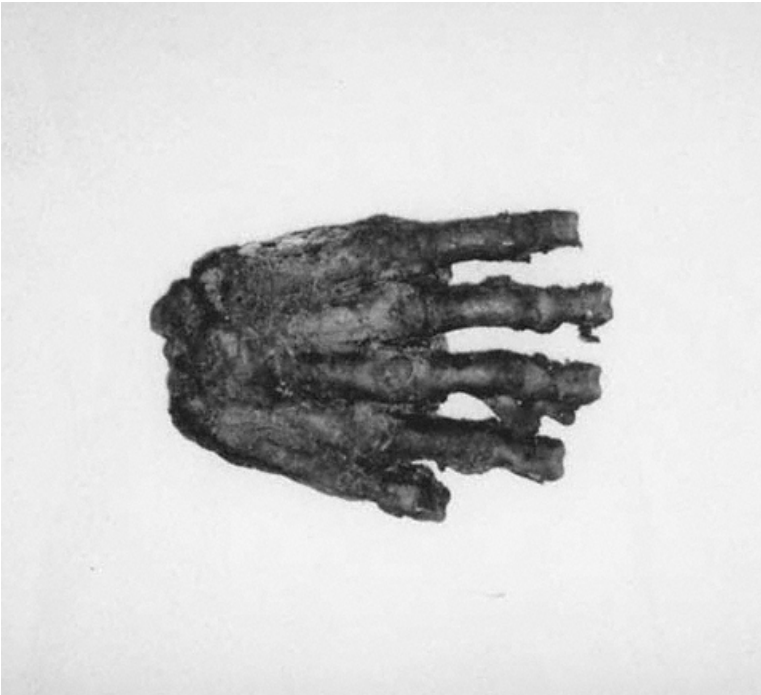

Figure 2.32 This skinned appendage was thought to be a hand when discovered by law enforcement. See next photo.

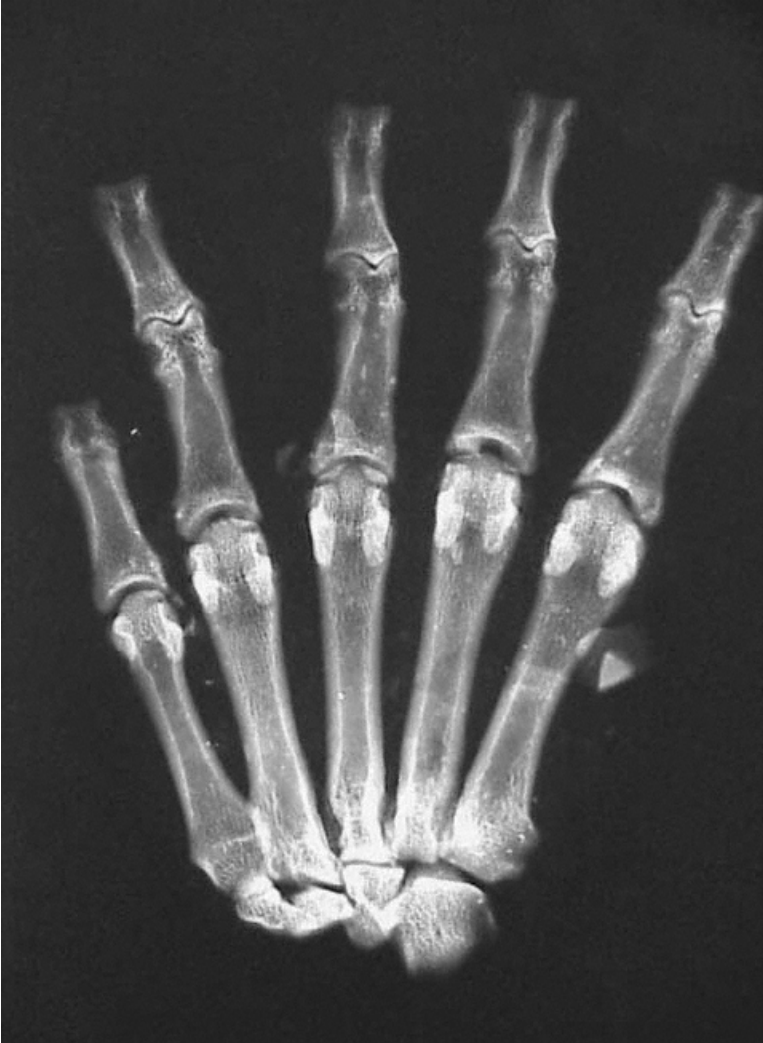

Figure 2.33 The X-ray reveals the specimen to be a bear paw. The tips of the digits were removed by a taxidermist for mounting. Notice that only one digit is shorter than the others.



Figure 2.34 These bones were sent in for examination. See next photo.

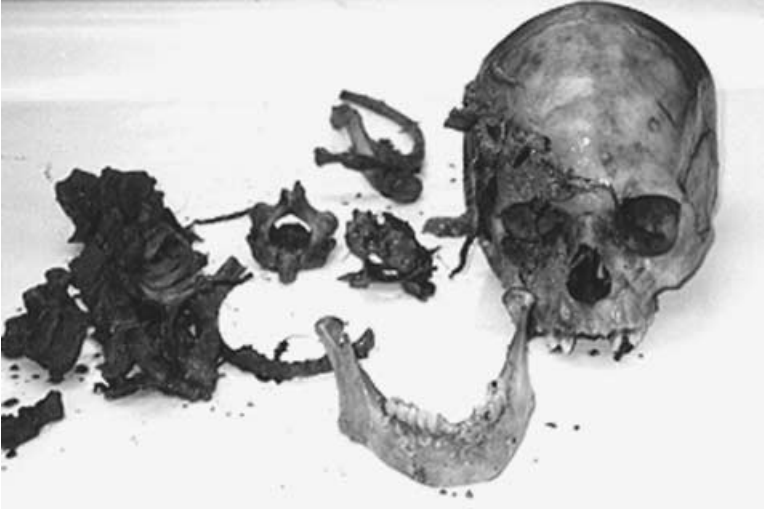

Figure 2.35 A closer view of the skull and jaw. See next photo.

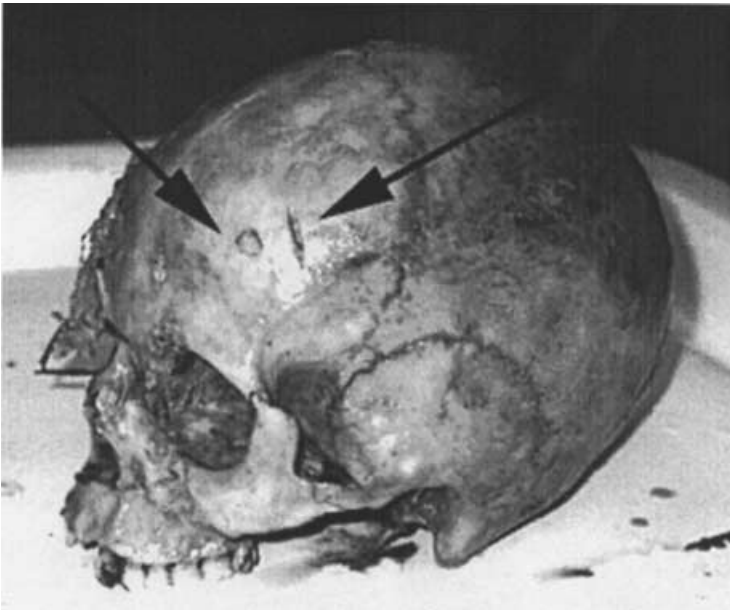

Figure 2.36 Examination of the skull revealed blunt impact injuries (arrows).

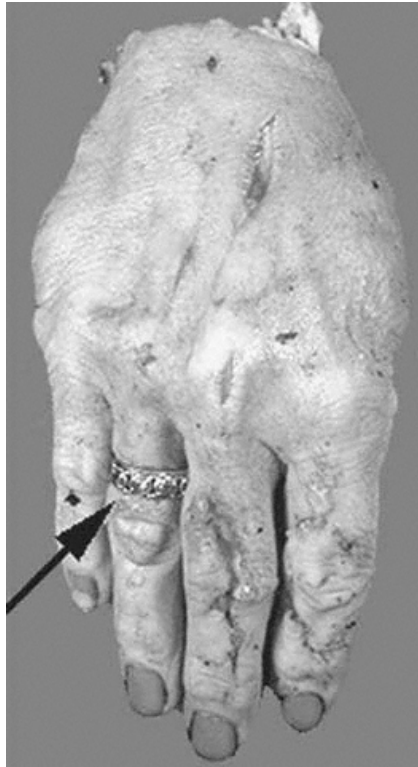

Figure 2.37 This hand is from a woman who died in a plane crash. The ring on her finger was identified by her son.

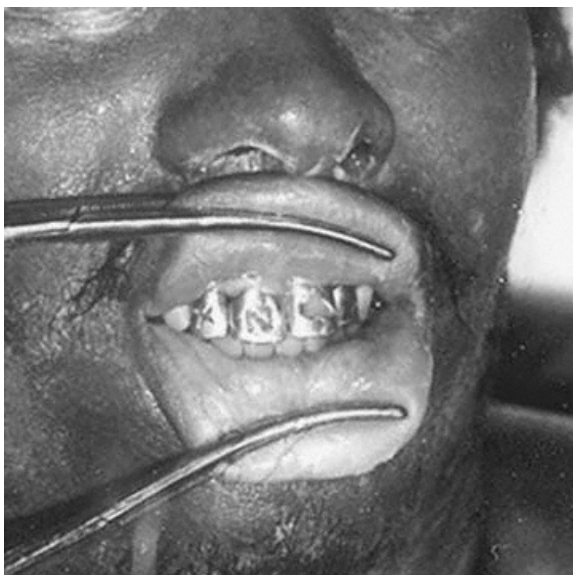


Figure 2.38 The gold caps with the initials made this a relatively easy I.D.

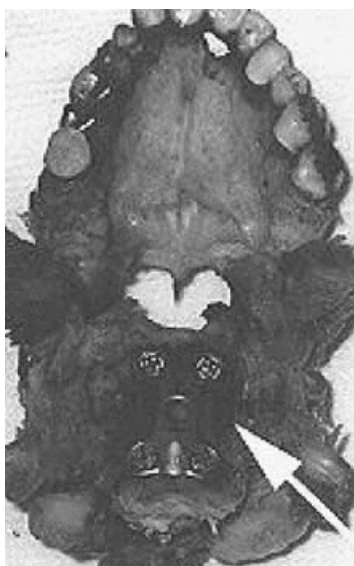

Figure 2.39 This photo shows a metal plate (arrow) used to fix a fractured cervical vertebrae. The plate has an identifying number that helped to make a positive I.D.

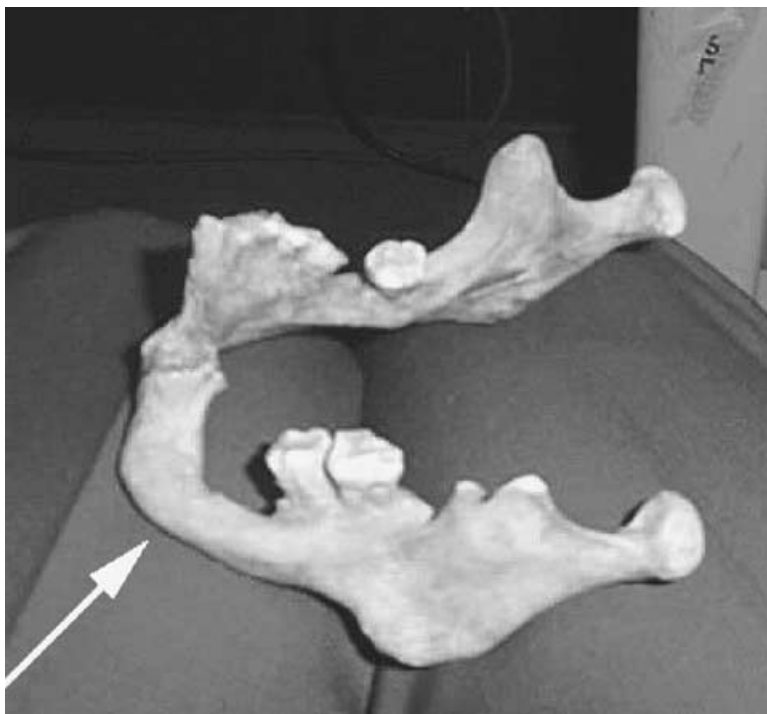


Figure 2.40 Old injuries to this decedent's jaw aided in the I.D. of the remains.

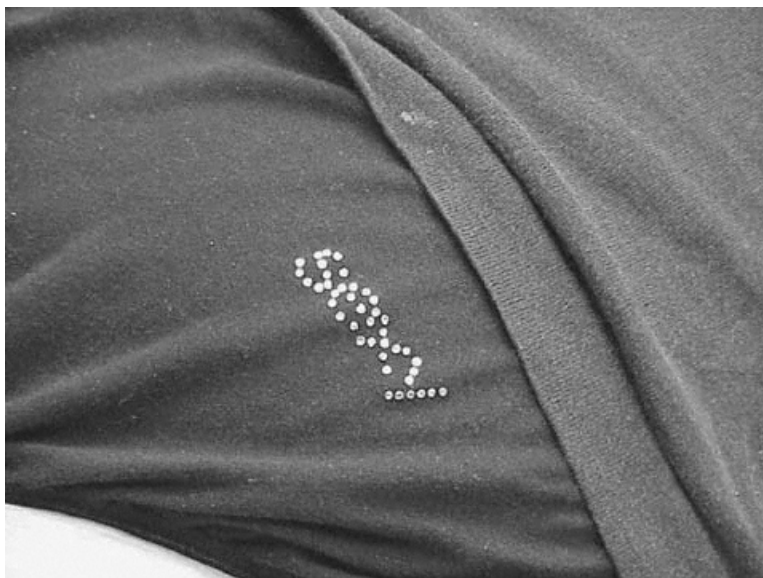

Figure 2.41 Clothing may be used to make probable I.D. The wearer of these panties was identified by the word "sexy."

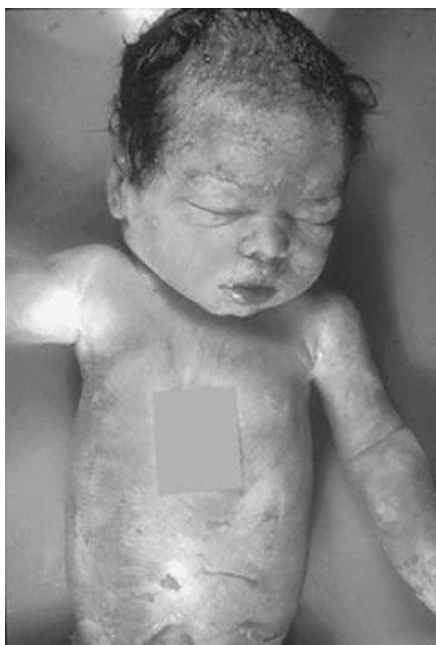

Figure 2.42 This baby was discovered in a toilet. His identification was made with DNA testing. Prior to DNA technology, his identification would probably have not been made.

References

1. Perper J.A., Time of death and changes after death. Pt 1. Anatomical considerations, in Spitz W.U. (ed): *Spitz and Fisher's Medicolegal Investigation of Death: Guidelines for the Application of Pathology to Crime Investigation*, 3rd ed. Springfield: Charles C. Thomas, 1993, pp 26-27.
2. *Dorland's Illustrated Medical Dictionary*, 28th ed. Philadelphia: W. B. Saunders, Co., 1994.
3. Fierro M.F., Identification of Human Remains, in Spitz, W.U. (ed): *Spitz and Fisher's Medicolegal Investigation of Death: Guidelines for the Application of Pathology to Crime Investigation*, 3rd ed. Springfield: Charles C. Thomas, 1993, pp 106-108.
4. Lee H.C., et al, DNA Typing in Forensic Science, *Am. J. Forensic Med. Pathol.*, 15:269-282, 1994.
5. Gonzales T.A., Vance M., et al., *Legal Medicine*. New York: Appleton-Century-Crofts, 1954.
6. Haglund W.D. and Sorg M.H. (eds): *Forensic Taphonomy*. Boca Raton: CRC Press, 1997.
7. DiMaio D.J. and DiMaio V.J.M.: *Forensic Pathology*. New York: Elsevier, 1989.
8. Graham M.A. and Hanzlick R.: *Forensic Pathology in Criminal Cases*. Carlsbad: Lexis Law Publishing, 1997.
9. *State of Missouri v. Ralph Davis*, 1989.

Case 1 — Differential Decomposition

On a hot August day in the midwest, the body of an elderly man was found in a ditch next to a country road. He was lying supine, dressed in overalls, a short-sleeved work shirt and socks without shoes. His abdomen and legs were covered by a blanket. There was extensive maggot infestation of the head and neck, partially obscuring a scalp defect on the back of his head. In addition, there was a ligature encircling the neck. The skin of the upper chest, neck and head was markedly darkened. The rest of the body was not decomposed. There was no apparent blood on the ground surrounding the decedent.

The scalp defect was a 4" gaping laceration with no injury to the underlying bone or brain. The ligature was a small towel tightly compressing the neck and knotted in the back. There was no rigor mortis and livor mortis was present on the posterior aspect of the body. The stomach contained fragments of sausage, brown liquid and yellow-white semi-solid food particles. Approximately a dozen maggots were collected and preserved in alcohol. A diagnosis of ligature strangulation was rendered. The manner of death was ruled as homicide.

The next day, a deputy sheriff called the pathologist and asked about the time of death. The deputy was holding a man in custody who had been seen with the decedent two days prior to the body being found. The suspect was out of town on business the day before the victim's body was discovered. The suspect had a good motive for the murder because of a soured business deal with the victim. Prior to making a formal arrest, the officer needed to make sure the postmortem interval was consistent with two days. What should the pathologist tell the deputy about the postmortem interval in this case?

Discussion

One of the most frequently asked questions during a death investigation concerns the time of death. Unfortunately, determining the exact time of death from an examination of a body is not possible. Numerous findings must be interpreted to give a reasonable estimate of the postmortem interval. In this particular case, the time of death was key to the arrest because the suspect had an alibi for the day prior to the discovery of the body.

In this case, differential decomposition occurred because a head injury caused an open wound. Blood is an excellent stimulus for flies to lay eggs and for maggot activity which accelerated decompositional changes of the head. Since the rest of the body had not decomposed, an estimation of the postmortem interval was made by evaluating the area of least decomposition.

Environmental temperature is the most important factor in determining the rate of decompositional change after death. The decompositional changes in the head and the lack of rigor mortis could occur in 10–20 hours in temperatures circa 90°F. Therefore, in this case the appearance of the body suggested a postmortem interval of less than 24 hours.

The decedent's stomach contained pieces of sausage, brown liquid and yellow-white food particles suggestive of breakfast foods. If he normally ate these foods only in the morning, then he probably ate breakfast on the day of his death. Relatives and friends should be contacted to discover his eating habits, including whether he tended to eat breakfast at home or at a particular restaurant. In addition, a search of his home may demonstrate remnants of sausage and eggs.

The maggots appeared freshly hatched and were also consistent with being less than 30 hours of age. This information correlates with the other findings since it is well established that flies lay eggs on a body very shortly after death.

The above discussion suggests the decedent died the day before his body was discovered. Therefore, the “prime” suspect with the strong alibi does not appear to have committed the murder, and investigators need to renew their search for the killer.

Case 2 — Time of Death

An elderly couple was discovered dead in bed. There was a gunshot wound to the man's head. A revolver was in his right hand. The woman had no apparent injuries. Both bodies were at room temperature, in complete rigor mortis and with posterior fixed lividity. The man was dressed in day clothes and his wife was wearing a nightgown. Autopsies demonstrated the woman to have a massive intracerebral hypertensive hemorrhage and the man to

have a perforating gunshot wound of the head with a contact entry site in the right temple.

The times of death and not the causes of death were in question. The man had a trust fund for his two grown children by a previous marriage. The trust was written in such a way that if he died first, his money went to his current wife. Upon her death, the money would go to her children by a previous marriage. But if he died after her, his children inherited the money. Thus, the important question is — who died first?

The physical appearance of the bodies was of no help. Both had relatively the same degree of rigidity and lividity. An analysis of their stomach contents was of no help since both stomachs were empty. The most important factor in this case was the clothing. The woman was wearing a nightgown and the man was wearing street clothes. Although there is no way to absolutely prove the sequence of events, the most likely scenario is that the man discovered his wife dead and subsequently laid down beside her and took his own life. In this scenario, his children would have received the money. Even though this scenario is the most likely, it cannot be proven scientifically to a reasonable degree of certainty. The wife's heirs may likely dispute such a ruling and claim that survivorship cannot be determined with reasonable certainty.

In many cases involving multiple deaths occurring in a single incident such as a plane crash, the sequence of deaths cannot be reliably determined. The fact that one person was pronounced dead after another person does not necessarily imply that death occurred later; it may simply reflect that one person was found before the other. Most jurisdictions deal with this issue by presuming that individuals who died in the same event died at the same time unless it can be proven otherwise to a reasonable degree of certainty.

Case 3 — Gastric Contents

A prison inmate summoned the guards at approximately 4:30 p.m. on a Sunday afternoon. When the guard arrived at the cell, the inmate told him he had just killed his cell mate during a fight within the previous 30 minutes. The cell mate was lying on the bottom bunk in the cell. The guard saw little out of the ordinary besides the dead cell mate. The guard called for the paramedics and did not examine the body. The autopsy demonstrated signs of strangulation — bruises on the neck, hemorrhages in the neck strap muscles, a fractured larynx and petechiae on the conjunctivae and orbital skin. The stomach was full of slightly digested brown meat with corn and lima beans.

The gastric contents were not consistent with other investigative information. On Sunday, the noon meal is served in the main cafeteria and the

evening meal is served in the cells. The evening meal is served early on Sunday, at approximately 3 p.m. On this particular day, a guard delivered two trays of the afternoon meal at the usual time. Thirty minutes later, the guard picked up the trays and both meals had been eaten. On this particular day, the noon meal was meatloaf with corn and lima beans. The evening meal consisted of more meat but with carrots as the only vegetable. Since the decedent had corn and lima beans in his stomach, he had been killed prior to the 3 p.m. meal and both of the evening meal trays had been eaten by the assailant. The killer admitted to killing his cell mate because he wanted to be on death row with his “boyfriend.” His wish was granted.